



CODEN [USA]: IAJPBB

ISSN: 2349-7750

INDO AMERICAN JOURNAL OF
PHARMACEUTICAL SCIENCES

<http://doi.org/10.5281/zenodo.1064397>Available online at: <http://www.iajps.com>

Case Report

A CASE REPORT ON BENIGN PROSTATIC HYPERPLASIA WITH HOMEOPATHIC REMEDIES

Nayak C¹, Hati AK², Dash SK², Paital B³¹Homoeopathy University, Saipura, Sanganer, Jaipur, Rajasthan, India²Dr. Abhin Chandra Homoeopathic Medical College and Hospital, Bhubaneswar, India³Department of Zoology, CBSH, Orissa University of Agriculture and Technology,
Bhubaneswar, India**Abstract:**

Benign prostatic hyperplasia (BPH) is characterized by proliferation of the cellular elements of the prostate. The complications faced by elderly people need to be minimized and most of elderly don not prefer a surgical approach. Therefore, treatment of BPH with medicines is prioritized by elderly people. The present case report adds a little to the field that how to treat BPH cases in elderly without surgical approach but with homeopathic formulations. Case report presented here is diagnosed case of BPH having grade III prostatomegaly on USG. Patient presented with increased frequency of urination in feeble stream and sudden urging occasionally. Patient was treated with homoeopathic medication and assessed using Ultrasonography, International Prostate Symptom Score, and Uroflowmetry with significant improvement. Hence, it is suggestive that homoeopathic treatment could be effective in the management of cases of BPH in elderly people.

Keywords: Homoeopathy, BPH, Uroflowmetry, International Prostate Symptom Score (IPSS), Constitutional medicine, Organopathic medicine, Sabal serrulata.

Corresponding Author:**Dr. Biswaranjan Paital**

Assistant Professor

Department of Zoology

Orissa University of Agriculture and Technology

College of Basic Science and Humanities

Bhubaneswar-751003, Odisha, India

Email: biswaranjanpaital@gmail.com

QR code



Please cite this article in press as Nayak C et al., *A Case Report on Benign Prostatic Hyperplasia with Homeopathic Remedies*, Indo Am. J. P. Sci, 2017; 4(11).

INTRODUCTION:

Benign enlargement of prostate occurs after 50 years [1], usually between 60 to 70 years [2]. Benign Prostatic Hyperplasia (BPH) affects both glandular epithelium and connective tissue stroma [2]. Benign hyperplasia of the stroma and epithelial cells of the prostate results in lower urinary tract symptoms (LUTS) such as post-void dribbling, increased urinary frequency and urgency, nocturia and weak urinary stream [3]. Frequency of urination is the earliest symptom and other symptoms are : difficulty in micturition; the stream is variable, dribbles towards end of micturition. Pain occurs with cystitis or acute retention of urine. Occasionally, there is retention of urine [1, 2]. On digital rectal examination, a non-tender, smooth, elastic, and firm enlarged prostate is found [1].

Homeopathic system of treatment is one of alternative medicines originally conceptualized by a German allopathic physician Samuel Hahnemann in late 18th century. His one of the main concepts was "let likes be treated by likes" (*similia similibus curentur*) and there was no concept of surgical approach initially in Homeopathy. On the other hand, BPH is a male specific elderly issue and the patients at late age always do not prefer surgical approach to treat it. More often, they wish to avoid this route of surgery and are deeply inclined to take the advantage of alternative treatment mode such as homeopathic remedies. In this context, many homeopathic medications are claimed to be effective against certain benign tumours including BPH, albeit lack of systematic literature on it make the claim groundless. Therefore, the present case study was aimed to test the effects of homeopathic remedies on a BPH case.

One previous study was undertaken to evaluate the effects of either *constitutional medicines* or *organopathic medicines* prescribed alone or constitutional medicine followed by organopathic medicine to the patients suffering from BPH. The case report presented below is a part of the said study [4]. Cases treated in Homoeopathy need to be reported with evidences in order to scientifically establish this system as evidence-based medicine. Homeopathic treatment has shown good results in the management of BPH as shown in the case report below, assessed through USG, Uroflowmetry and International Prostate Symptom Score (IPSS).

MATERIALS AND METHODS:**Case profile**

A 65 years old male presented with signs and symptoms of BPH for last 1 year. He had frequent urge for urine, every half an hour during day and 2-3

times at night, with feeble stream. Patient had a feeling as if some urine remained after urination. Patient's other minor complaint included: pain in right inguinal region with mild numbness in morning.

Patient was of average built and height with grey hair. He was a hot patient; summer was intolerable and he wanted constant fanning and liked bathing. He had craving for *sweets* and meat.

Patient was mild in nature but obstinate. He liked company. He was fastidious, jovial, always hurried and hasty without any marked anxiety. The patient was a farmer, married and addicted to bidi. He had past history of sexual excess and chickenpox. He was operated for left-sided inguinal hernia 10 years back. His father died of *malignant brain tumour*. Patient took allopathic medication for 1 month for the symptoms related to BPH, with temporary relief only.

On examination- Prostate gland was enlarged; upper limit could not be reached. Both lobes equally enlarged, firm, elastic; median sulcus well-felt, mucosa mobile.

Symptomatic assessment was done by IPSS score, Ultrasonography and Uroflowmetry were done in laboratory and presented as before and after treatment conditions.

Remedy selection

Considering the *family history of cancer*, the mental and physical general symptoms as well as presenting complaints of the patient, *Carcinosin* was selected as the *constitutional medicine* and *Sabal serrulata* as supportive *organ remedy*, for the patient. *Carcinosin 200 / 1* dose followed by *Sabal serrulata* ϕ 10 drops, thrice a day were administered.

RESULTS:

After taking *Carcinosin 200* and *Sabal serrulata* ϕ, during subsequent visits every month, the patient reported improvement in urinary flow, frequency of urination and other common symptoms of BPH. He was prescribed *Placebo 200* followed by *Sabal serrulata* ϕ to continue as before. After seven months, the patient reported no further improvement, when he was prescribed *Staphysagria 1M/1* dose, basing upon the mental symptoms and past history of the patient (inguinal hernia was operated), besides presenting complaints, followed by *Sabal serrulata* ϕ as before. During subsequent visits, the patient reported overall improvement, in terms of common symptoms of BPH. During this period, his pain in right inguinal region also subsided. So, all medicines were stopped. It was observed that IPPS was decreased from 21 to 9 (Table 1 and 2). Similarly, the

residual urine volume was decreased from 104 ml to 11 ml (Fig. 1 and Table 3). On the other hand, the maximum uroflowmetry was increased from 10 ml/sec to 20 ml/sec. Average uroflowmetry was

increased from 6 ml/sec to 11 ml/sec. The void volume was also increased from 189 ml to 408 ml (Fig. 2).

Table 1: International Prostate Symptom Score (IPSS) of 21 before treatment.

Sl No	Questions to be answered	None	Less than once every 5 times	Less than once every 2 times	About once every 2 times	more than once every 2 times	Almost always
1	Have you felt like your bladder is not completely empty after urination in the past month?	0	1	2	3	4	5
2	Have you had to go to the toilet within 2 hours of doing so in the past month ?	0	1	2	3	4	5
3	Have you had disrupted urination in the past month ?	0	1	2	3	4	5
4	Have you found it hard to control your urine in the past month ?	0	1	2	3	4	5
5	Have you had a case of weak urinations in the past month?	0	1	2	3	4	5
6	Have you had to strain to initiate urination in the past month?	0	1	2	3	4	5
		None	Once	Twice	3 times	4 times	5 times or more
7	How many times did you, on average, get up to urinate at night after going to bed in the past month ?	0	1	2	3	4	5
Score: 0-7 mild, 8-19: moderate, 20-35: severe.						IPSS Total score	
						21	

The scores obtained for the patient for the respective IPSS option are highlighted with bold numerical values.

Table 2: International Prostate Symptom Score (IPSS) of 9 after treatment.

Sl No	Questions to be answered	None	Less than once every 5 times	Less than once every 2 times	About once every 2 times	more than once every 2 times	Almost always
1	Have you felt like your bladder is not completely empty after urination in the past month?	0	1	2	3	4	5
2	Have you had to go to the toilet within 2 hours of doing so in the past month ?	0	1	2	3	4	5
3	Have you had disrupted urination in the past month ?	0	1	2	3	4	5
4	Have you found it hard to control your urine in the past month ?	0	1	2	3	4	5
5	Have you had a case of weak urinations in the past month?	0	1	2	3	4	5
6	Have you had to strain to initiate urination in the past month?	0	1	2	3	4	5
		None	Once	Twice	3 times	4 times	5 times or more
7	How many times did you, on average, get up to urinate at night after going to bed in the past month ?	0	1	2	3	4	5
Score: 0-7 mild, 8-19: moderate, 20-35: severe.						IPSS Total score	
						9	

The scores obtained for the patient for the respective IPSS option are highlighted with bold numerical values.

Table 3: Ultrasound Report of whole abdomen of the patient.

Organ	Before Treatment	After Treatment
Liver	Measures 13.5 cm, normal in size & echo texture. No dilatation of IHBR/ SOL seen.	Measures 13.5 cm, normal in size & echo texture. No dilatation of IHBR/ SOL seen.
Gall Bladder	Normal in shape & wall thickness. No evidence of any calculi/ SOL noted.	Normal in shape & wall thickness. No evidence of any calculi/ SOL noted.
Common bile duct	Measures 7 mm, proximal & mid CBD are normal. Distal CBD could not be evaluated properly due to over lying bowel gas shadow. No e/o any ductal calculus noted within visualized segment. PV measure 12 mm, normal in course & calibre.	Measures 7 mm, proximal & mid CBD are normal. Distal CBD could not be evaluated properly due to over lying bowel gas shadow. No e/o any ductal calculus noted within visualized segment. PV measure 12 mm, normal in course & calibre.
Spleen	Measure 9.2 cm. normal in size, outline & echo pattern	Measure 9.2 cm. normal in size, outline & echo pattern
Pancreas	Normal in size & echo texture. No evidence of any SOL/ Calcification/pancreatic duct dilatation noted	Normal in size & echo texture. No evidence of any SOL/ Calcification/pancreatic duct dilatation noted
Right kidney	Measure 10.6 x 4.4 cm. Normal in size, outline & echo texture. Cortical echo are normal with preservation of cortico medullary differentiation. No evidence of calculi/ hydronephrosis or SOL noted.	Measure 10.8 x 4.5 cm. Normal in size, outline & echo texture. Cortical echo are normal with preservation of cortico medullary differentiation. No evidence of calculi/ hydronephrosis or SOL noted.
Left kidney	Measure 11.2 x 5.2 cm. Normal in size, outline & echo texture. Cortical echo are normal with preservation of cortico medullary differentiation. No evidence of calculi/ hydronephrosis or SOL noted.	Measure 11.0 x 5.0 cm. Normal in size, outline & echo texture. Cortical echo are normal with preservation of cortico medullary differentiation. No evidence of calculi/ hydronephrosis or SOL noted.
Urinary Bladder	Well defined. Mild diffuse thickening of UB wall seen. Wall thickness measures 5 mm. Post void residual urine measure 11 ml. No e/o any calculi/ SOL noted	Well defined. Mild diffuse thickening of UB wall seen. Wall thickness measures 5 mm. Post void residual urine measure 11 ml. No e/o any calculi/ SOL noted
Prostate	Measure 5.4x4.9 x 4.5 cm (65 gms approx) grade III prostatomegally with homogenous echo texture. Capsule appears intact.	Measure 5.6x4.5 x 4.5 cm (60 gms approx) prostatomegally with homogenous echo texture. Capsule appears intact.
Lymph Gland	No retroperitoneal lymphadenopathy/ collection intact	No retroperitoneal lymphadenopathy/ collection intact
Impression	Grade III Prostatomegaly. Diffuse thickening of UB wall with Post Void Residual Urine volume - 104 ml	Prostatomegaly, Diffuse thickening of UB wall with Post Void Residual Urine volume -11 ml

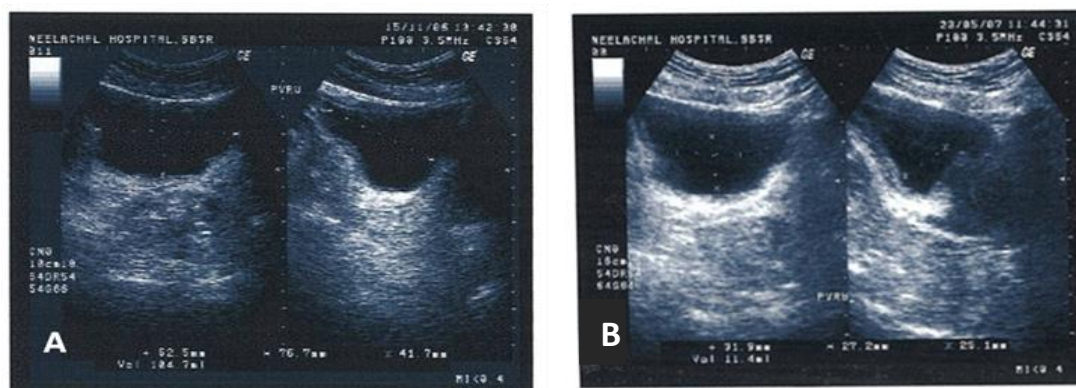


Figure 1: Ultrasonography before treatment with residual urine volume = 104 ml (A) and after treatment with residual volume 11 ml (B).

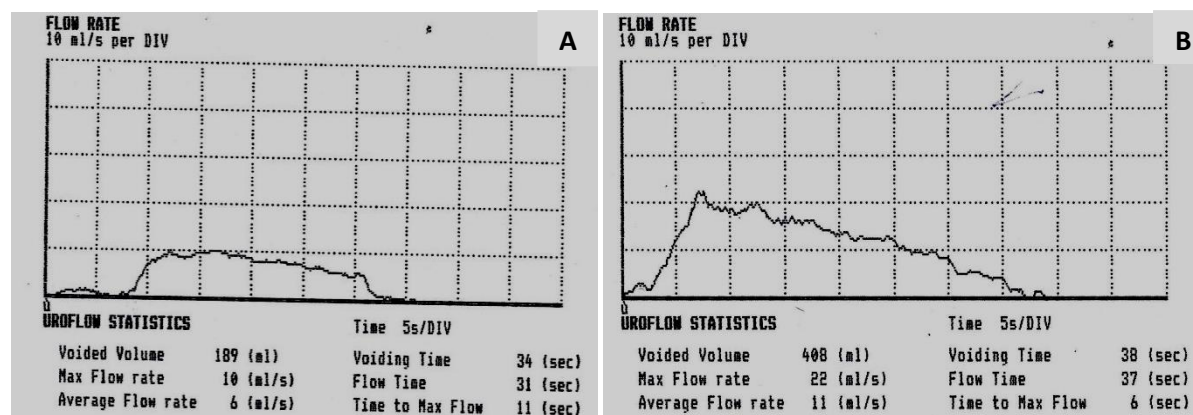


Figure 2: Uroflowmetry before treatment (A) having Max flow= 10ml /sec, average flow rate =6 ml/sec and after (B) treatment having Max flow= 22 ml/sec, average flow rate =11 ml/sec.

DISCUSSION:

As evident from the prescriptions made for the treatment of the patient, two aspects have been focussed, i.e. application of constitutional medicine and supported by organ remedy. Application of *constitutional medicine(s)* is the gold standard for *classical homoeopathy* treatment of chronic cases including BPH. The selection of constitutional medicine often is sometimes guiding by a few characteristic features only. In this case, *family history of cancer* and a few mental symptoms led to the selection of the similimum, i.e. *carcinosis*. The *role of family history* in deciding the similimum is also supported by other authors [5, 6].

Secondly, many clinicians believe that besides the administration of constitutional medicine, the application of organ specific medicine, as a supportive therapy, will expedite or facilitate the action of the former, particularly when there are pathological changes in the patient. This is supported by the outcomes of few other studies also and stated in a related protocol [8], where application of constitutional medicine followed by organ remedies has been recommended [4, 7]. In a three arm research study on BPH[4], the researchers have shown that the group of patients who received constitutional medicine(s) followed by organopathic medicine *Sabal serrulata φ* exhibited better results than those received *constitutional medicines* or *organopathic medicine (Sabal serrulata φ)* alone [4]. In the present case, *Carcinosin 200* and *Staphysagria 1M* supplemented with *Sabal serrulata φ*, yielded favourable outcomes not only in alleviating the troublesome symptoms of the patient, but also helped to bring down the pathological changes, to certain extent.

Foubister [6] who was the pioneer in introducing the medicine *carcinosis* in homoeopathic literature, got success in treating chronic cases with this medicine, selected on the basis of family history of cancer. Based on this concept *carcinosis* was administered to the patient in the present study. In Homoeopathic Materia Medica books, authors like Clarke [9] and Boericke [10] have recommended *Sabal serrulata* for enlargement of prostate. Moreover, in Homoeopathic Repertory books also, the authors such as Kent [11], Boger [12], Murphy [13] and Shroyens [14] have recommended for *Sabal serrulata* in BPH. In the present case, *Staphysagria* was prescribed as a constitutional medicine, which is also recommended for prostatic troubles by different authors such as Kent [11], Boericke [10], Boger [12], Shroyens [14] and Murphy [13]. Thus, all the three medicines prescribed for the patient in the present case on the basis of homoeopathic literature, yielded favorable results in alleviating the symptoms related to BPH, besides reducing the size of the prostate.

CONCLUSION:

This case is one of the evidence-based documented research studies, that shows effectiveness of homoeopathic treatment not only in relieving the symptoms of BPH, but also in bringing favorable changes in pathology. However, from practice point of view, a fixed treatment protocol cannot be recommended for the treatment of all patients suffering from BPH. Nevertheless, if we can document the pre-and post-evidences in support of treatment of a very common disorder like BPH, showing the benefit of homoeopathic treatment, it will not only further strengthen the scientific background of Homoeopathy, enrich our literature and add to the existing professional knowledge, but also enhance the confidence of the neophytes of Homoeopathy [15, 16, 17].

ACKNOWLEDGMENT

Contribution of Dr. Arun Kumar, M.D. (Hom.), Part-I, Dr. M.P.K. Homoeopathic Medical College, Hospital and Research Centre, Jaipur (Constituent College of Homoeopathy University, Jaipur) for proof reading the article is duly acknowledged.

REFERENCES:

1. Norman WS, Bulstrode CJK, O'Connell RP. editors. Bailey and Love's Short Practice of Surgery. 26th ed. London: CRC Press; 2013.
2. Bhat MS. 2016. SRB's Manual of Surgery. 5thed. New Delhi: Jaypee Brothers Medical Publishers (P) Ltd.
3. Medbulletscom. 2017. Available from: <https://www.medbullets.com/step2-3-renal/20708/benign-prostatic-hyperplasia-bph> [accessed on 21 October 2017].
4. Hati AK, Paital B, Naik KN, Mishra AK, Chainy GBN, Nanda LK. 2012. Constitutional, organopathic and combined homeopathic treatment of benign prostatic hypertrophy: a clinical trial. *Homeopathy* Oct; 101(4):217–23. doi:10.1016/j.homp.2012.08.005.
5. Dey SP. 2004. Clinical Case Reports on Constitutional Prescribing. 3rd ed. Howrah (W.B.) : Sm. Aparna Bhattacharya.
6. Foubister DM. 1975. The Carcinosis Drug Picture. Bombay: The Homoeopathic Medical Publishers.
7. Gupta G, Singh S. Role of homoeopathic medicines in prostate enlargement: A retrospective observational study. *Indian Journal of Research in Homoeopathy*, 2016; 10 (4):266-271.
8. Oberai P, Reddy GRC, Roja V, Sharma B, Narula RH. Homoeopathy therapy for lower urinary tract symptoms in men with Benign Prostatic Hyperplasia: An open randomized multicentric placebo controlled clinical trial. *Indian Journal of Research in Homoeopathy* .2014; 8(2):75-80.
9. Clarke JH. 1995. A Dictionary of Practical Materia Medica,. Vol III. Reprint ed. Delhi: B.Jain Publishers Pvt LTD;
10. Boericke W. 1906. Pocket Manual of Homoeopathic Materia Medica comprising the Characteristic & Guiding Symptoms of all Remedies. New York: Boericke & Runyon.
11. Kent JT. 1995. Kent's Repertory of Homoeopathic Matria Medica Expanded. Second ed. New Delhi: B. Jain Publishers Pvt. Ltd.
12. Boger CM. 1996. Boenninghausen's Characteristics Materia Medica & Repertory with Word index. Reprint ed. New Delhi: B. Jain Publishers (P) Ltd.
13. Murphy R. 2016. Homoeopathic Medical Repertory- A Modern Alphabetical and Practical Repertory. Third Revised ed., 5th impression. Noida(U.P.): B. Jain Publishers (P) Ltd.
14. Shroyens F. 1993. Synthesis- Repertorium Homoeopathicum Syntheticum. London, Homoeopathic Book Publishers.
15. Sahoo AR, Paital B, Taneja D, Hati AK. Knowledge, Attitude and Practice of Anganwadi Workers on Homoeopathic Formulations. *Indo American J Pharmaceutical Res.*2017; 7 (10):574-581.
16. Paital B, Hati AK, Nayak C, Mishra AK, Nanda LK. 2017. Combined Effects of Constitutional and Organopathic Homeopathic Medicines for Better Improvement of Benign Prostatic Hyperplasia Cases. *International Journal of Clinical and Medical Images*, 2017; 4(7):1-2. doi: 10.4172/2376-0249.1000574
17. Paital B, Hati AK, Naik KN, Mishra AK, Nanda LK, Chainy GBN. 2014. Re: Editorial Comment on Constitutional, Organopathic and Combined Homeopathic Treatment of Begin Prostatic Hypertrophy: A Clinical Trial: S. A. Kaplan *J Urol* 2013; 190: 1818-1819. *J. Urol.*, 193, 1-2. doi.org/10.1016/j.juro.2014.04.088.