CODEN [USA]: IAJPBB ISSN: 2349-7750

INDO AMERICAN JOURNAL OF
PHARMACEUTICAL SCIENCES

http://doi.org/10.5281/zenodo.1465007

Available online at: http://www.iajps.com *Research Article*

OUTCOME AND POST OPERATIVE COMPLICATIONS OF EMERGENCY APPENDICECTOMY DONE FOR APPENDICULAR MASS

[1]Dr. Muhammad Irfan Shahzad Anjum, [2]Dr. Abdur Rehman, [2]Dr. Hania Nisar

[1]MO at BHU 474/GB, Faisalabad

[2]Allied Hospital, Faisalabad

Abstract:

Objective: *To evaluate the results of the emergency appendicectomy for appendiceal mass in terms of hospital stay and postoperative complications.*

Study design: *A series of descriptive cases.*

Venue and Duration: *In the Surgical Department, Allied Hospital, Faisalabad for one year duration from April 2017 to April 2018.*

Methodology: *Fifty patients with appendiceal masses / abscesses were selected and emergency appendectomy was performed. The main outcome measures were hospital stay (during the day) and postoperative complications. Complications were classified as wound infection; bruise; No more abscesses in the peritoneal cavity and fecal fistula. SPSS 11 version was applied to the data.*

Results: *The total complication rate was 28% (16%) including wound infection, (6%) wound hematoma, (4%) residual abscess, and fecal fistula formation (2%). The mean duration of hospital stay (± SD) was 4.96 (± 4.89) days, ranging from 3 to 35 days.*

Conclusion: *Emergency appendectomy is a safe and effective treatment modality for the management of the appendix.*

Key Words: *Appendiceal mass, appendicitis, emergency appendectomy.*

Corresponding author:

Dr. Muhammad Irfan Shahzad Anjum,

MO at BHU 474/GB,

Faisalabad

QR code

Please cite this article in press Muhammad Irfan Shahzad Anjum et al., ***Outcome and post operative complications of emergency appendicectomy done for appendicular mass.****, Indo Am. J. P. Sci, 2018; 05(10).*

INTRODUCTION:

Acute appendicitis is the most common cause of surgical emergencies requiring acute abdomen and early surgery. Delay of intervention may lead to the development of generalized peritonitis or appendiceal mass. Tumor formation is one of the targets after appendicitis. Pathologically, it may represent a spectrum ranging from phlegmon to abscess. Phlegmon is an inflammatory mass consisting of adjacent internal organs and omentum, while the second appendicular mass contains pus containing pus. Although the surgical treatment of acute appendicitis has been widely accepted, the management of the appendicular mass is controversial and can be treated in a variety of ways. Standard treatment for appendicitis is conservative treatment followed by appendectomy after 6 to 10 weeks. Low morbidity, decreased hospitalization, low cost, and patient compliance favored surgical management of the appendix mass by experienced surgeons in favor of preventive applications of conservative treatment following appendectomy. The aim of this study was to evaluate the results of emergency appendicectomy for appendiceal mass in terms of hospital stay and postoperative complications.

MATERIALS AND METHODS:

This series of descriptive study was held in the Surgical Department, Allied Hospital, Faisalabad for one year duration from April 2017 to April 2018. A probabilistic sampling technique was used. This study involved patients with mass of appendicitis and written consent of the preoperative diagnosis of anesthesia in patients under anesthesia by giving palpation prior to a surgical procedure (in which the protection of the abdominal wall has influenced the assets in 12 years). Exclusion criteria, such as ovarian cysts, ileocecal tuberculosis, and cecum carcinoma, have been found to be unfavorable in surgical and other pathologies. Senior residents / main registrars performed abdomen exploration from the right inferior paramedian incision. Adhesions were cut very carefully to avoid involuntary damage to neighboring structures. Any pus found was aspirated and taken for culture and sensitivity. Depending on the difficulty encountered, antegrade or retrograde appendectomy was performed with chromic catgut without invagination appendicitis stump. This drain was placed in the peritoneal cavity (paracolic gutter and pelvis) and in any case the drainage was performed. The skin was mainly approached. The proforma was filled by patients with recorded demographics (age and gender), clinical presentations, (day) appendicular mass were used to document the findings especially during the duration, (in minutes) and duration of the operation. Interest rates included hospital stay (daytime) and postoperative complications. Complications were classified as wound infection; bruise; In the peritoneal cavity and stool fistula residual abscesses (ie, the drain from the continuous intestinal contents and / or discharge of the intestinal contents through the wound). SPSS for Windows (version 11, SPSS Inc., Chicago, IL, USA) software program was used for all statistical analyzes. If the qualitative variables were in percentages and frequencies, the mean ± SD (standard deviation) was used to calculate the quantitative variables.

RESULTS:

Of the 50 patients studied, 31 (62%) were male and 19 (38%) were female. The male to female ratio was 1.6: 1. The ages of the patients were between 12 and 64 and the mean age was 33.26 (± 13.01). Pain was a feature of the mean duration (± SD) of the appendicitis mass that was 2.38 (± 1.43) days (2-7 days) in almost all patients.

Symptoms	Score
Migratory right iliac fossa pain	1
Anorexia	1
Nausea/Vomiting	1
Signs	
Tenderness in right iliac fossa	2
Rebound tenderness	1
Elevated temperature	1
Laboratory Findings	
Leucocytosis	2
Shift to the left of neutrophils	1
Total score	**10**

Figure 1 shows the remainder of the clinical presentations. During the operation, 15 (30%) patients had phlegmon properties, and 35 (70%) patients had appendicular abscess. The mean operation time (± SD) was 42.44 (± 6.46) minutes. The total complication rate was 28% (Table I).

Table I. Post-operative complications

Complications	No.	%
Wound infection	8	16
Hematoma	3	6
Residual abscessess	2	4
Fecal fistula	1	2
Total	14	28

Wound infection was observed in 8 (16%) patients. They were all treated to dress up alone. One patient (2%) developed a fecal fistula with a low yield 9 days after appendectomy. This was treated conservatively and closed for a period of five weeks. The remaining abscesses (4%) were treated with antibiotics and ultrasound-guided drainage (indicated). The mean duration of hospital stay (± SD) was 4.96 (± 4.89) days, ranging from 3 to 35 days.

DISCUSSION:

In the past, conservative treatment has been considered a safe and effective way to treat the appendicular mass. With the advent of antibiotics, designed to prevent the growth of anaerobes, and the availability of experienced surgeons, early appendectomy can now be performed without complications. It not only improves the disease of the disease, but also eliminates the need for appendectomy in subsequent applications. Tumor formation is the result of a walled ruptured insert and is usually 48 h after inflammation is taken into adjacent adjoining structures.

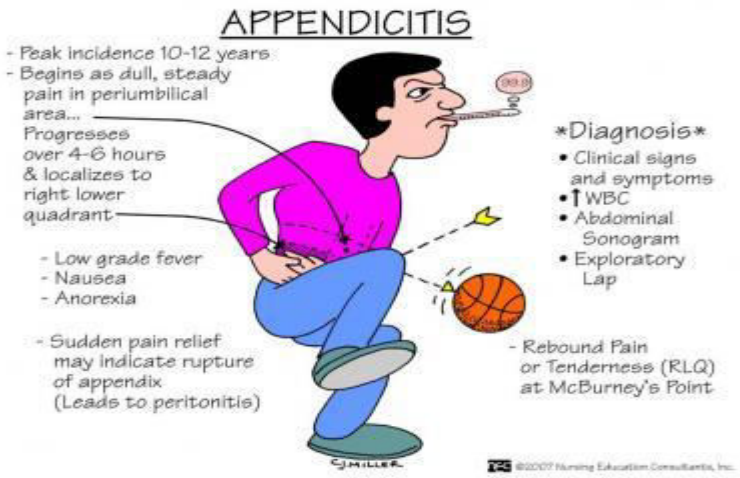

In this study, the mean duration of appendix mass formation was 2.38 days (2-7 days). The result is similar to the study conducted by Choudry.Clinically, the clear distinction between the appendicular mass and abscess is often difficult and the diagnosis is confirmed in the examination. Jordan also mentioned this series earlier. The mean operative time in this study was 42.44 minutes. Han and his partners pointed out that the average study time was 29.38 ± 3.19 minutes in his study of 1142 patients who performed an emergency appendicitis for an almost comparable appendicular mass to this study. The morbidity after early appendectomy is the main problem of avoiding this treatment method in cases of appendiceal mass. The total complication rate in this study was 28%. The rate of complications in the series of 638 cases with routine appendectomy was 43.1% compared to Ohene-Yeboah and Togbe fairly high Study. In the present study, wound infection (16%) was a higher morbidity. They were all managed conservatively with bandages alone. In the Taj and Qureshi series, the rate of wound infection was 18.75%. Arshad and colleagues also noticed 19.31% of the wound sepsis. In this study, residual hematoma and abscesses were recorded in 6% and 4% of the patients. These are similar to Choudry's results. Fecal fistula detected in 2% of the cases was treated conservatively and spontaneously closed within 5 weeks. Choudry also found a case of fecal fistula pospendectomy in a series of fifty patients who recovered spontaneously within 4 weeks.

CONCLUSION:

In the presence of an appendicular mass, emergency appendectomy is a safe and effective treatment modality with the added benefit of returning the patient to a normal lifestyle before conventional treatment.

REFERENCES:

1. Young, Katelyn A., Nina M. Neuhaus, Marcus Fluck, Joseph A. Blansfield, Marie A. Hunsinger, Mohsen M. Shabahang, Denise M. Torres, Kenneth A. Widom, and Jeffrey L. Wild. "Outcomes of complicated appendicitis: Is conservative management as smooth as it seems?." *The American Journal of Surgery* 215, no. 4 (2018): 586-592.
2. Senapati, J.N., Pani, J.R., Samal, A. and Mondal, R., 2018. A COMPARATIVE STUDY OF EMERGENCY APPENDECTOMY VS CONSERVATIVE MANAGEMENT IN CASES OF EARLY APPENDICULAR LUMP IN A TERTIARY CARE HOSPITAL. *INDIAN JOURNAL OF APPLIED RESEARCH*, *7*(8).
3. Yadav, Padmini, Suresh Prasad Shah, Rakesh Kumar Gupta, and Brikh Raj Joshi. "Randomized controlled trial comparing clinical outcome and cost analysis between laparoscopic and open appendicectomy for acute appendicitis at Dharan, Sunsari, Nepal." *International Surgery Journal* 5, no. 4 (2018): 1205-1212.
4. Elkbuli, Adel, Brandon Diaz, Valerie Polcz, Shaikh Hai, Mark McKenney, and Dessy Boneva. "Operative versus non-operative therapy for acute phlegmon of the appendix: Is it safer? A case report and review of the literature." *International journal of surgery case reports* 50 (2018): 75-79.
5. Baba, Toure Fode, Wade Thomas Marcel Mbar, Diao Mohamed Lamine, S. M. Aly, Tendeng Jacques Noel, C. Mamadou, T. C. Tidiane, and Konate Ibrahima. "Appendicular plastron: emergency or deferred surgery: a series of 27 cases collected in the surgical clinic of the Aristide Le Dantec Hospital." *The Pan African medical journal* 29 (2018): 15-15.
6. Kochi, Mitsugu, Hiroshi Suda, Masashi Fujii,

Ken Hagiwara, Hiroko Shimizu, Megumu Watanabe, Yoritaka Matsuno, Takaharu Kawai, Renpei Yagi, and Tadatoshi Takayama. "Diagnostic performance of surgical criteria incorporating MDCT for suspected acute appendicitis." *International Surgery*(2018).

7. Foster, Deshka, Will Kethman, Lawrence Z. Cai, Thomas G. Weiser, and Joseph D. Forrester. "Surgical Site Infections after Appendectomy Performed in Low and Middle Human Development-Index Countries: A Systematic Review." *Surgical infections* 19, no. 3 (2018): 237-244.
8. Al-Kurd, Abbas, Ido Mizrahi, Baha Siam, Amram Kupietzky, Nurith Hiller, Nahum Beglaibter, Ahmed Eid, and Haggi Mazeh. "Outcomes of interval appendectomy in comparison with appendectomy for acute appendicitis." *Journal of Surgical Research* 225 (2018): 90-94.
9. Hutchings, N., Wood, W., Reading, I., Walker, E., Blazeby, J.M., van't Hoff, W., Young, B., Crawley, E.M., Eaton, S., Chorozoglou, M. and Sherratt, F.C., 2018. CONTRACT Study-CONservative TReatment of Appendicitis in Children (feasibility): study protocol for a randomised controlled Trial. *Trials*, *19*(1), p.153.
10. Nishizawa, T., Maeda, S., Goldman, R.D. and Hayashi, H., 2018. Predicting need for additional CT scan in children with a non-diagnostic ultrasound for appendicitis in the emergency department. *The American journal of emergency medicine*, *36*(1), pp.49-55.
11. Tang, Xiao-Huan, Chao Chen, Yuan-Da Liu, Xiao-Fang Qiao, Hao Liu, Zhi-Ming Ma, Jia-Ming Zhu, and Jing-Jing Liu. "Case Report A rare postoperative complication of perforated appendicitis: necrotizing fasciitis." *Int J Clin Exp Med* 11, no. 9 (2018): 10126-10130.
12. Yousef Y, Youssef F, Dinh T, Pandya K, Stagg H, Homsy M, Baird R, Laberge JM, Poenaru D, Puligandla P, Shaw K. Risk stratification in pediatric perforated appendicitis: Prospective correlation with outcomes and resource utilization. Journal of pediatric surgery. 2018 Feb 1;53(2):250-5.
13. Vaos, George, Anastasia Dimopoulou, Eleana Gkioka, and Nick Zavras. "Immediate surgery or conservative treatment for complicated acute appendicitis in children? A meta-analysis." *Journal of pediatric surgery* (2018).
14. Sartelli, M., Baiocchi, G.L., Di Saverio, S., Ferrara, F., Labricciosa, F.M., Ansaloni, L., Coccolini, F., Vijayan, D., Abbas, A., Abongwa, H.K. and Agboola, J., 2018. Prospective observational study on acute appendicitis worldwide (POSAW). *World Journal of Emergency Surgery*, *13*(1), p.19.
15. van den Boom, Anne Loes, Elisabeth ML de Wijkerslooth, Joost van Rosmalen, Frédérique H. Beverdam, Evert-Jan G. Boerma, Marja A. Boermeester, Joanna WAM Bosmans et al. "Two versus five days of antibiotics after appendectomy for complex acute appendicitis (APPIC): study protocol for a randomized controlled trial." *Trials* 19, no. 1 (2018): 263.