



CODEN [USA]: IAJPBB

ISSN: 2349-7750

**INDO AMERICAN JOURNAL OF
PHARMACEUTICAL SCIENCES**<http://doi.org/10.5281/zenodo.4384671>Available online at: <http://www.iajps.com>**Research Article****EVALUATE WHETHER FLAP DESIGN AND DURATION OF SURGERY MAY INFLUENCE SYMPTOMS AND ACUTE POSTOPERATIVE SIGNS AFTER EXTRACTION OF THE LOWER THIRD OF THE MOLARS**¹Dr Wahhab Ahmad, ²Maryam Rani¹Mayo Hospital Lahore²Punjab Dental Hospital Lahore**Abstract:**

Aim: Diverse careful factors expected to assume a part in postoperative course after lower third molar extraction. The point of study was to evaluate whether fold plan and term of a medical procedure can affect intense postoperative symptoms and signs after lower third molar extraction.

Methods: Twenty-nine patients who were scheduled for lower third molar extraction were selected for this investigation and were randomly assigned to two groupings to fold configuration: group A (envelope fold) and group B (three-sided fold). Growth and lockjaw studied during a medical procedure on days 0, 2 and 7. Our current research conducted at Lahore General Hospital, Lahore from March 2017 to February 2018. Torment assessed for seven days after the medical procedure. The extreme torment after the procedure was chosen as the primary outcome variable. The ANOVA was used to study the contrasts between the clustering of the greatest postoperative agony, lockjaw and growth at days 2 and 7. Pearson's connection coefficient used to study the relationship between the duration of a medical procedure and postoperative indications and signs.

Results. No critical contrast was found between the two fold plans for any postoperative indications and signs. The term of a medical procedure was discovered to be associated with both lockjaw ($r = -0.45$, $P = 0.07$) and expanding ($r = 0.58$, $P = 0.004$) as surveyed 2 days after medical procedure. No affiliations were found between length of a medical procedure and most extreme postoperative agony and lockjaw and expanding at 7-day span.

Conclusion: Inside the restrictions of the current investigation, the term of a medical procedure, and not the fold configuration, influenced the intense postoperative manifestations and signs after lower third molar extraction.

Keywords: Flap Design, Postoperative Signs, Lower Third, The Molars.

Corresponding author:

Dr. Wahhab Ahmad,
Mayo Hospital Lahore

QR code



Please cite this article in press Wahhab Ahmad *et al.*, Evaluate Whether Flap Design And Duration Of Surgery May Influence Symptoms And Acute Postoperative Signs After Extraction Of The Lower Third Of The Molars, *Indo Am. J. P. Sci.*, 2018; 05(06).

INTRODUCTION:

Careful removal of the lower third of the molar is a common procedure in oral medicine and is regularly associated with significant adverse postoperative effects [1]. Intense confusion includes side effects, similar to torment, and signs such as expansion and trims [2]. It is realized that many conservative factors, similar to the bending plane or scope of the intercession, may influence the postoperative experience after extraction of the lower third of the molar, however, various examinations have introduced different results [3]. It is certainly widely perceived that the extension of the activity term causes greater postoperative morbidity. Otherwise, the effect of the bending plane on intense postoperative manifestations and signs is less clear. Many examinations have found an alternative postoperative course in the formulation of the folding plan, the less extensive fold being for the most part the one that causes the fewest complaints [4]. However, a few investigations failed to find distinctions in side effects and postoperative signs using different folding plans. The purpose of this investigation was to evaluate whether the bending plane and the scope of a medical procedure can have an impact on the intense postoperative manifestations and signs after the extraction of the lower third of the molars [5].

METHODOLOGY:

29 consecutive patients without medication (19 women and 7 men; mean age: 28.89 ± 10.76 years, age range: 19-65 years) scheduled for extraction of the lower third of the molars at a walking site were selected for this examination. All patients had full inclusion of the third molar in the mucosa, and no past or present irritation or torment was considered here. Our current research was conducted at Lahore General

Hospital, Lahore from March 2017 to February 2018. Avoidance models included subjects of sufficient age (<18 years), analyzed mental problems, analyzed neurological diseases, analyzed impaired informational or psychological abilities, contraindications to non-steroidal mitigating drugs or amoxicillin. The review was foreseen by the Declaration of Helsinki and approved by the local Ethics Committee. Each patient gave a compounded and instructed participation agreement. All careful procedures were performed by a similar dental specialist, as indicated by the standard conventions of anesthesia and care used at the dental center. Mepivacaine (3%) containing 1:100,000 of adrenaline was used as a sub alveolar, buccal and lingual nerve block. Patients were randomly divided into two groups according to fold configuration: Group A (envelope folding) and Group B (three-sided folding). The division was done to acquire two homogeneous clusters for sexual orientation and age. In group A, a secular entry point was made buccal from the first to the second mandibular molar with a distal cut along the mandibular branch. In harvest B, an entry point was made from the mandibular branch to the distobuccally part of the next molar. At this point, it was transformed into a secular cut to the distobuccally edge of the primary molar, where a delivery cut was made (Figure 1). Outside the entry point, the mediation was equivalent for both harvests. Lingual tissue was removed and fixed, buccal and distal bone was removed with brambles, separation of the teeth was performed with pods where vital, and sutures were placed to achieve essential or auxiliary closure, as appropriate. No prescriptions were taken prior to the extraction of the teeth. The "duration of a medical procedure" was characterized as the time elapsed between the height of the fold and the end of the stitch.

Figure 1:

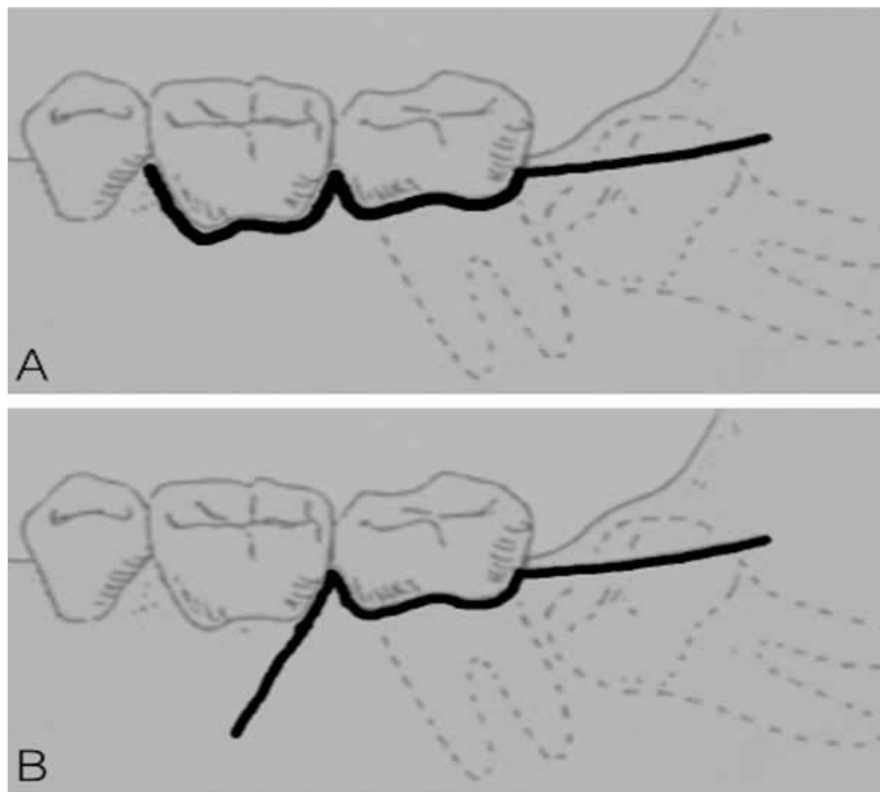


Figure 2:

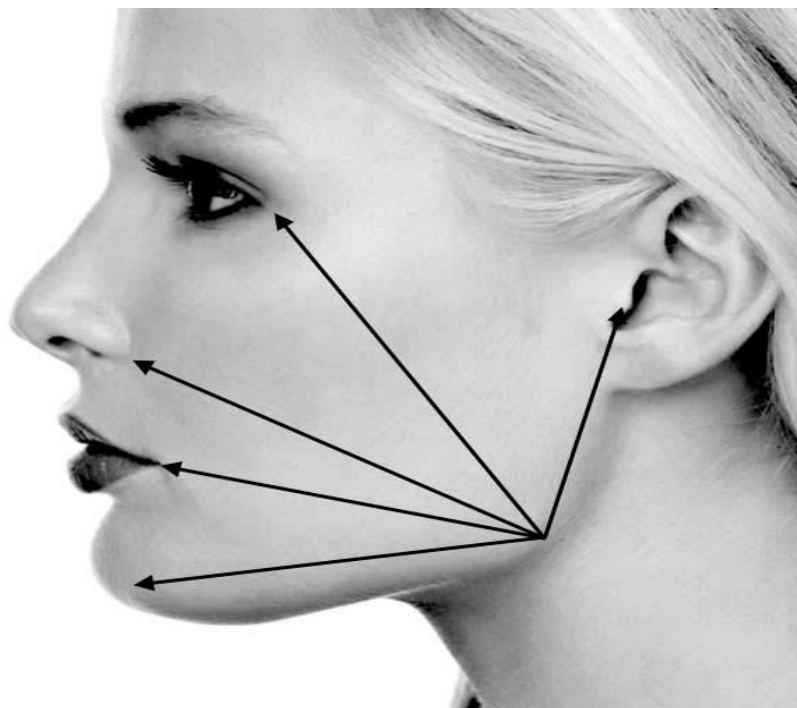


Figure 3:

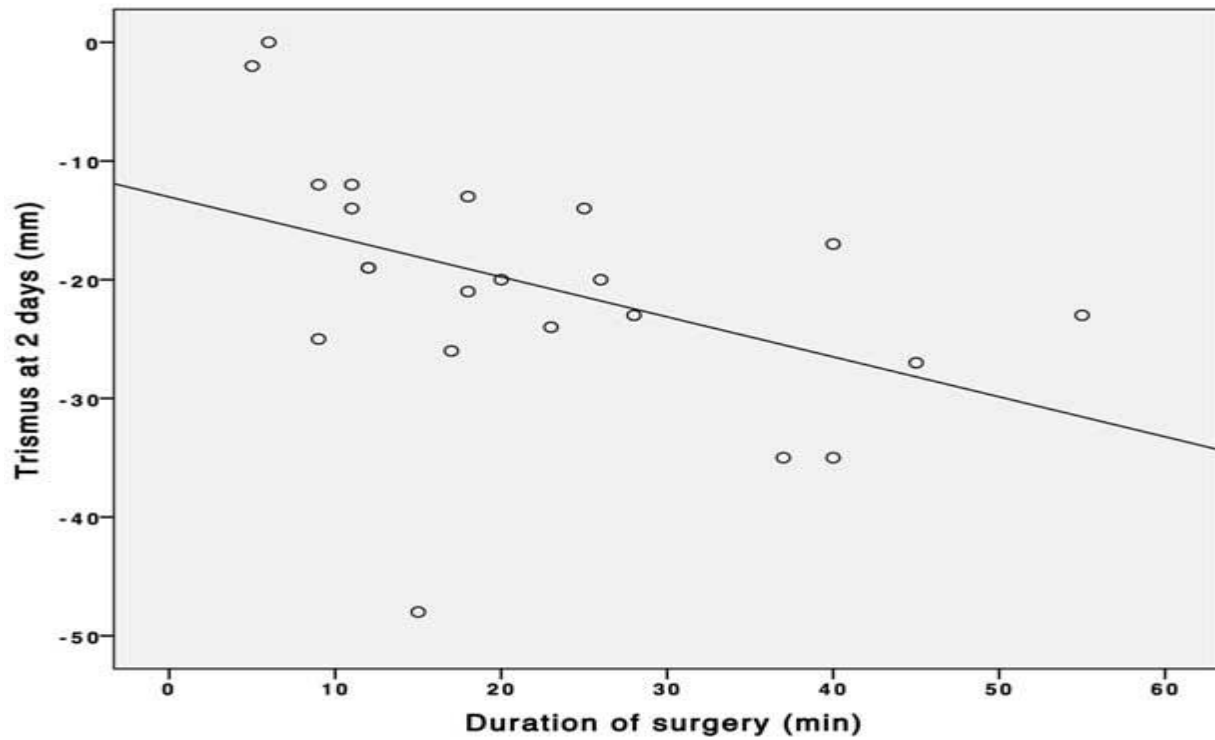
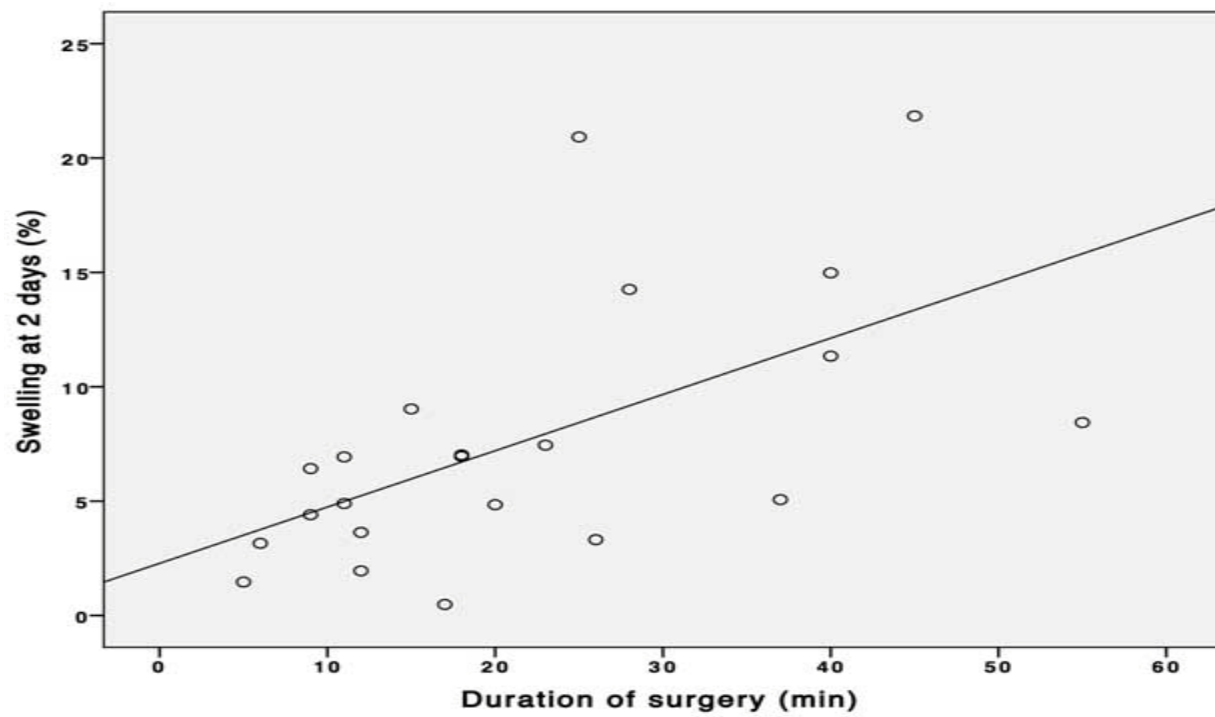


Figure 4:



RESULTS:

Table 1 presents the means (and standard deviations) of the indications and postoperative signs in the two groupings. No critical distinction was found between the two folding planes for indications and postoperative signs. It was found that the duration of medical intervention was related to both jaw locking

($r = -0.46$, $P = 0.05$, Figure 3) and expansion ($r = 0.59$, $P = 0.006$, Figure 4), assessed two days after expulsion of the third molar. No affiliation was found between the duration of a medical procedure and the most extreme postoperative torment and lock-jaw and expansion during the 7 days of postoperative extension.

Table 1:

Variables	Groups	
	Group 1	Group 2
Subjects (number)	13	12
2-days trismus (mm)	-22.33 (12.18)	-16.29 (4.23)
7-days trismus (mm)	-9.41 (8.23)	-7.13 (8.93)
2-days swelling (%)	6.6 (5.57)	9.97 (5.98)
7-days swelling (%)	2.12 (1.93)	1.17 (3.06)
Maximum post-operative pain (100-mm VAS)	57.06 (22.08)	48.75 (30.32)

DISCUSSION:

Extraction of the lower third of the molar is regularly associated with postoperative grime. A variety of conservative strategies have been developed to perform less invasive mediation and thus reduce side effects and postoperative signs [6]. To this end, less widened folds have been proposed. In the current review, two different folding plans were analyzed: a simple intramuscular envelope fold without an exit cut and a three-sided fold with an exit cut [7]. The three-sided fold mostly makes an upper and wider incision, it is expected to create more provocative edema and thus more postoperative signs. In fact, many examinations have revealed the most terrible postoperative course when enlarged folds are applied [8]. In the current investigation, however, no distinction has been found in the manifestations and signs with regard to the fold plan, which is reliable with the various examinations detailed in the literature. The main variable of postoperative discomfort seemed, by all accounts, to be the duration of the medical intervention. Such a result is usually announced in writing [9]. A survey showed a relationship between the duration of the medical intervention and the postoperative side effects and signs after third molar surgery. Such an affiliation was predictable: the longer the duration of the tissue

damage, the higher the measure of the provocation of intermediaries; thus, it may well be an impression of the severity of torment, expansion and blockage of the jaw [10].

CONCLUSION:

Within the limits of the current investigation, it is conceivable to assume that the duration of a medical procedure and not the configuration of the folds may have an impact on the intense postoperative manifestations and signs after the extraction of the lower third of the molars.

REFERENCES:

1. Rosa AL, Carneiro MG, Lavrador MA, Novaes AB Jr. Influence of flap design on periodontal healing of second molars after extraction of impacted mandibular third molars. *Oral Surg Oral Med Oral Pathol Oral Radiol Endod.* 2002;93:404–7. [[PubMed](#)] [[Google Scholar](#)]
2. Hashemipour MA, Tahmasbi-Arashlow M, Fahimi-Hanzaei F. Incidence of impacted mandibular and maxillary third molars: a radiographic study in a Southeast Iran population. *Med Oral Patol Oral Cir*

- Bucal. 2013;18:e140–5. [[PMC free article](#)] [[PubMed](#)] [[Google Scholar](#)]
3. Trakinienė G, Šidlauskas A, Trakinis T, Andriuškevičiūtė I, Šalomskienė L. The Impact of Genetics and Environmental Factors on the Position of the Upper Third Molars. *J Oral Maxillofac Surg.* 2018;76:2271–9. [[PubMed](#)] [[Google Scholar](#)]
 4. Hyam DM. The contemporary management of third molars. *Aust Dent J.* 2018;63:S19–26. [[PubMed](#)] [[Google Scholar](#)]
 5. Medina-Solís CE, Mendoza-Rodríguez M, Márquez-Rodríguez S, De la Rosa-Santillana R, Islas-Zarazua R, Navarrete-Hernández JD. Reasons why erupted third molars are extracted in a public university in Mexico. *West Indian Med J.* 2014;63:354–8. [[PMC free article](#)] [[PubMed](#)] [[Google Scholar](#)]
 6. Ahmed Asif J, Yusuf Noorani T, Khursheed Alam M. Tooth Auto-transplantation: An Alternative Treatment. *Bull Tokyo Dent Coll.* 2017;58:41–8. [[PubMed](#)] [[Google Scholar](#)]
 7. McArdle LW, McDonald F, Jones J. Distal cervical caries in the mandibular second molar: an indication for the prophylactic removal of third molar teeth? Update. *Br J Oral Maxillofac Surg.* 2014;52:185–9. [[PubMed](#)] [[Google Scholar](#)]
 8. Kalantar Motamedi MR, Heidarpour M, Siadat S, Kalantar Motamedi A, Bahreman AA. Orthodontic Extraction of High-Risk Impacted Mandibular Third Molars in Close Proximity to the Mandibular Canal: A Systematic Review. *J Oral Maxillofac Surg.* 2015;73:1672–85. [[PubMed](#)] [[Google Scholar](#)]
 9. Jerjes W, El-Maaytah M, Swinson B, Banu B, Upile T, D'Sa S. Experience versus complication rate in third molar surgery. *Head Face Med.* 2006;2:14. [[PMC free article](#)] [[PubMed](#)] [[Google Scholar](#)]
 10. Alqahtani NA, Khaleelahmed S, Desai F. Evaluation of two flap designs on the mandibular second molar after third molar extractions. *J Oral Maxillofac Pathol.* 2017;21:317–8. [[PMC free article](#)] [[PubMed](#)] [[Google Scholar](#)]