



CODEN [USA]: IAJPBB

ISSN: 2349-7750

INDO AMERICAN JOURNAL OF PHARMACEUTICAL SCIENCES

<http://doi.org/10.5281/zenodo.1487964>

Available online at: <http://www.iajps.com>

Research Article

FUNCTIONAL DIAGNOSTICS FOR CHILDREN IN THE PERMANENT DENTITION PERIOD

Dudnik O.V.¹, Mamedov A.A.¹, Dybov A.M.¹, Kharke V.V.¹, Zubkov A.V.¹

FSAEI of HE I.M. Sechenov First Moscow State Medical University of the Ministry of
Health of the Russian Federation (Sechenov University)

¹Department of Pediatric Dentistry and Orthodontics

Olesya V. Dudnik, Candidate of Medical Science – oldudnik87@mail.ru

Adil A. Mamedov, MD, Head of the Department of Pediatric Dentistry and Orthodontics -
mmachildstom@mail.ru

Andrew M. Dybov, Candidate of Medical Science – amdybov@gmail.ru

Viktoriya V. Kharke, Candidate of Medical Science, Senior lecturer of the Department of Pediatric Dentistry
and Orthodontics - vikaharke@mail.ru

Artiom V. Zubkov, postgraduate – zubkovstomat@gmail.com

Abstract:

The aim of the study was to improve the efficiency of orthodontic treatment, by use of MPI Mandibular Position Indicator. 34 patients aged 14 to 18 years were examined, of which 12 patients were included in the treatment group and divided into two groups of 6 people each. All patients underwent orthodontic treatment using the bracket system of active self-ligation of the direct arc technique, using the anthropometric system of quantitative estimation (The ABO Model Grading System) at the stage of alignment. Early orthodontic treatment and at the end of his patients first and second groups we analyzed the closing of dentition in centric occlusion and centric relation. As a diagnostic tool using the mandible position indicator MPI (Mandibular Position Indicator). In group 2, where the ABO system was used during the alignment phase with the repeated reframing of the required braces using the indirect bonding method, the ΔZ indicator for the right and left sides fixed by the MPI method was lower than in group 1 at a very high level of statistical significance $p = 0.000003$ and $p = 0.00077$, respectively). The mean values of the ΔX indicator for the left side in group 2 had a statistically confirmed downward trend compared to group 1 ($p = 0.051342$).

Key words: orthodontic treatment, Mandibular Position Indicator, diagnosis, adjustment, central occlusion, centric relation

Corresponding author:

Olesya V. Dudnik,

Postal address: Off.: 204, 2-4 Bolshaya Pirogovskaya st.,

Moscow 119991, Russia

E-mail: oldudnik87@mail.ru

Fax: +7(499) 248-01-81

Telephone number: +79260900362

QR code



Please cite this article in press Olesya V. Dudnik et al., *Functional Diagnostics for Children in the Permanent Dentition Period.*, Indo Am. J. P. Sci, 2018; 05(11).

INTRODUCTION:

In recent years interest in orthodontic treatment the dentoalveolar of anomalies at adolescents and adults has grown both in Russia and abroad (Fadeyev R.A., 2002; Proffit W.R., 2008; Horoshilkina F.Ya., 2011; Okeson J. 2011; Arsenina O.I., 2012; Persen of Hp, 2015), and improvement of methods of treatment of this group of the population is explained by considerable prevalence the dentofacial of anomalies and consequently, high needs (from 20% to 75%) in special treatment [1, 4].

In this regard, the special value to achieve a high quality result of orthodontic treatments, are gained by the newest development of the effective principles of diagnostics of anomalies of dentomaxillofacial system.

Experience of foreign colleagues (Roth R.H., 1981; Andrews L.F., 1989; Lee R.S., 1989; Proffit W.R., 2008; Okeson J., 2011) shows that studying in TMJ is a close connection with biomechanics and other questions of gnathology [2, 3, 5, 6].

However, if key concept to be as the centric relation, central occlusion, a rest position, etc., they aren't considered by many doctors when they planning their orthodontic treatment. Literature data analysis has shown that there is an interdependent communication of dental health and TMJ. Frequently, the compensatory and adaptive system of the chewing device creates prerequisites of development of pathologies from TMJ and conversely [3]. Therefore normalization of a bite at children's age is the leading factor of optimum functional occlusion at mature age.

Purpose

Improving the efficiency of orthodontic treatment, by using of Mandibular Position Indicator (MPI).

MATERIALS AND METHODS:

When performing a research 34 patients aged from 14 up to 18 years old with the diagnosis - dense position of teeth in the top and a mandible without disturbance of provision of gnathic bones were examined, of which 12 patients were included in medical group.

At selection in group the following criteria were used:

1. Age of patients of 14-18 years, period of a constant occlusion.
2. Patients at the orthodontist weren't treated earlier.
3. Dentoalveolar forms an orthognathic occlusion.

4. Symmetric growth maxilla and mandible.

5. Dense position of teeth on maxilla and a mandible does not exceed 4 mm.

6. Lack of the impacted teeth according to an orthopantomography, except for the third molar teeth maxilla and a mandible.

7. Sanitized oral cavity. Safe anatomy of crowns of teeth.

Patients of medical group were divided into two groups of 6 people in everyone. In this case –in each group there was a peer number of men and women. All patients were underwent orthodontic treatment to use the bracket system to active self-ligation as direct bonding technique, by using the ABO Model Grading System, they were developed by the American Board of Orthodontics in 1999, during the adjustment phase [7].

Patients who were treated with the standard protocol of orthodontic treatment, they were assigned to the first group.

The second group was consisted of patients who underwent repeated re-fixation of brackets by the indirect bonding method at the beginning of the adjustment stage, after anthropometrical measurements by using the ABO quantification method.

In addition to the generally accepted basic and additional survey methods, at the beginning and end of the treatment, patients in the first and second groups were analyzed for the closing of the dentition in the central occlusion and the central relation. As a diagnostic tool to determining the difference in the position of the caput mandibulae in the central occlusion and in the central relation, the MPI mandibular position indicator was used.

The MPI device registers change in the position of the mandible in three mutually perpendicular planes graphically and allows one to represent that is a change in millimeters. It is possible only in those cases when there are no structural changes in the tissues of the joint - the caputs, discs, capsules and ligaments (Bumann A., Lotzmann U., 2000). The device is a modified upper part of the articulator "SAM", but instead of articulate pits has two cubes with labels that lead into contact with the articular balls of the lower part of the articulator (Fig. 1. a, b).




Fig. 1. The mandibular position indicator (a), MPI is installed instead of the upper frame of the articulator (b).

The Variation and the statistical handling are carried out by the methods, commonly accepted for medicobiological researches: calculation of arithmetic averages of sizes, an average square deviation, representativeness error for each parametes, comparison of the average sizes by criterion of U-Mann-Whitney and T-Wilcoxon with reliability of distinctions in case of ($p < 0,05$) by means of a software package of EXCEL 14.1.0 (Microsoft).

RESULTS AND DISCUSSION:

The values of functional analysis in this study of facial features and occlusion who were separated to two different groups before treatment shown that the following features.

The analysis of the functional relationship was carried out in the oral cavity and articulaire.

Intraoral analysis of the functional ratio in the patients of the group 1 and group 2 shown that in all 12 subjects in the central relation in the easily occlusal contact, a symmetrical contact of the chewing teeth is observed, and only with strong compression of the jaws is the occlusal contact of all groups of teeth, including the incisors.

In the MPI analysis prior to treatment, all 12 (100%) subjects had a mismatch in the position of the mandibular joints in the central occlusion and the central relation of the jaws. What, as it was revealed According to the data of the literature study, can create the prerequisites for the development of pathologies from the TMJ, and also be one of the reason for the instability of the results of orthodontic treatment.

At the same time, statistically significant intergroup differences could not be identified (Figure 2).

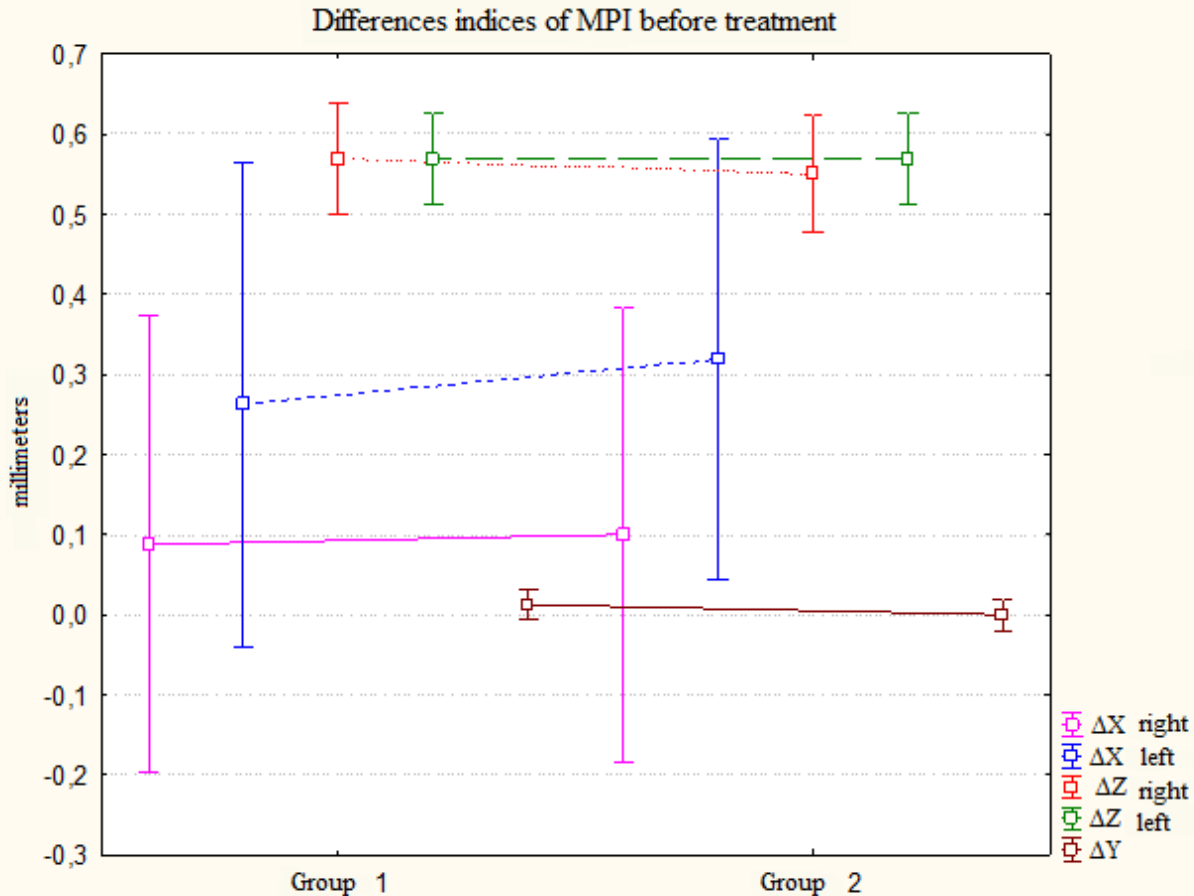


Fig. 2. Differences indices of MPI before treatment in groups 1 and 2.

After the active treatment, in the group 1, patients underwent treatment according to the standard scheme, in MPI analysis 2 (33.3%) patients were in normal limits, in 4 (66.6%) patients there was a mismatch in the position of the joint heads the mandible in the central occlusion and the central relation of the jaws, which is later requirement to correct the therapeutic or orthopedic interventions.

In group 2, patients were treated by using the anthropometrical system of quantitative evaluation of ABO during the adjustment phase, and then re-fixing the incorrectly arranged brackets by the indirect bonding method, in MPI analysis the discrepancy between the central occlusion and the central relation was not revealed, in 2 patients (33, 3%) the

difference did not exceed 0.5 mm, which is considered the norm.

A statistical analysis of the differences showed that in group 2, where the ABO system was used during the alignment phase with the repeated reframing of the required braces by the indirect bonding method, the ΔZ indicator for the right and left sides fixed by the MPI method was lower than in group 1 at very high level of statistical significance ($p = 0.000003$ and $p = 0.00077$, respectively). Mean values of the ΔX indicator on the left side in group 2 had a statistically confirmed downward trend compared to group 1 ($p = 0.051342$) (Figure 3).

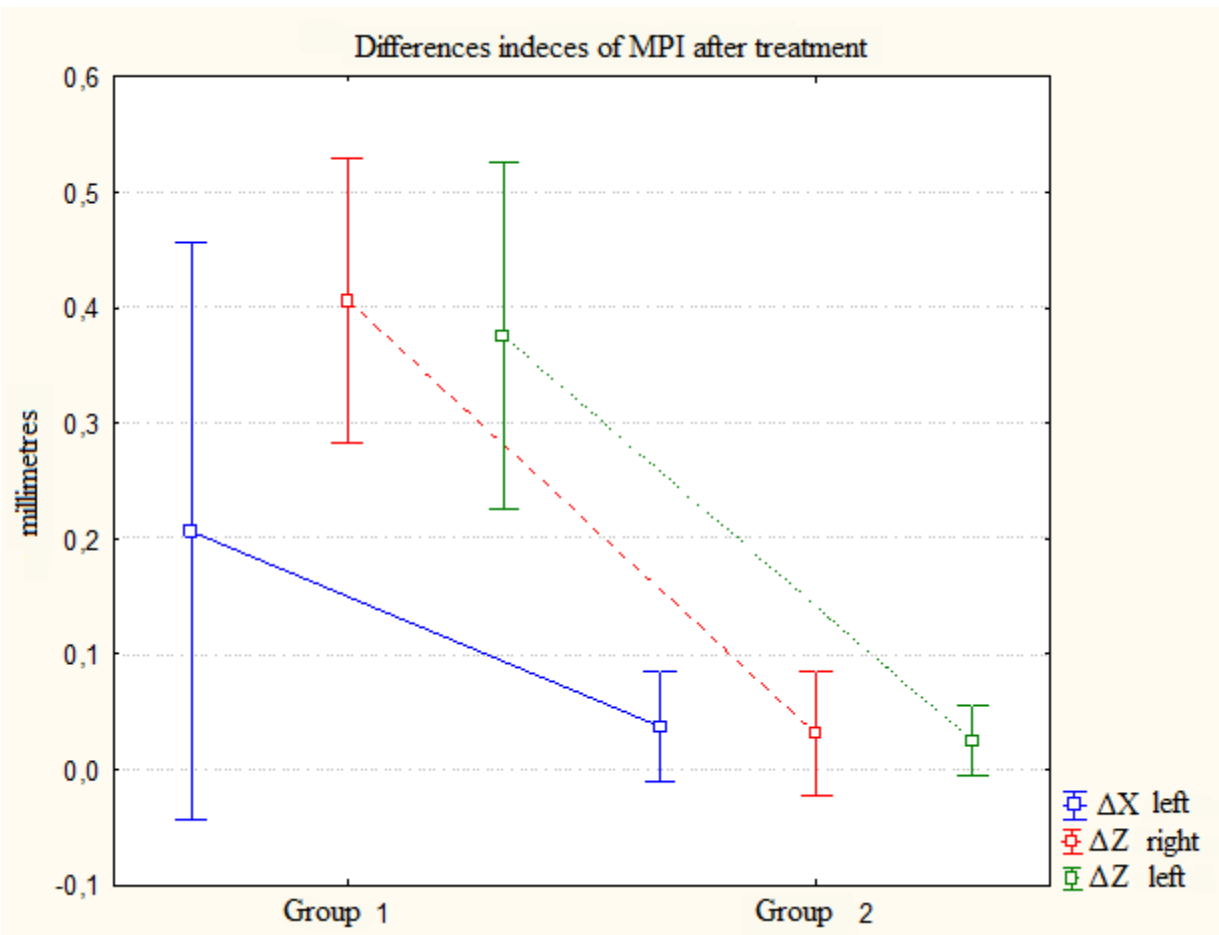


Fig. 3. Comparison of the results of the analysis of functional occlusion in groups 1 and 2 at the end of treatment.

CONCLUSION:

Accordingly, the use of the MPI mandible position indicator as a rapid diagnostic method allows one to determine the unity of the central occlusion and the central relation, which in turn makes it possible to obtain a stable result of orthodontic treatment, minimizing the occurrence of relapses and the development of pathological processes with the sides of the dentoalveolar complex.

REFERENCES:

- Persin L. S. Ortodontia. — M.: GEHOTAR-Media, 2015.
- Andrews L. F. Straight wire: the concepts and appliance // LA Wells -1989. — 120 p.
- Khvatova V. A. Functional diagnostics and treatment in dentistry. M.: Medical book; 2007
- Khoroshilkina F. Ya., Persin L. S., V. P's Okushko-Kalashnikova. Orthodontia. Prophylaxis and treatment of functional morphological and esthetic disturbances in dentoalveolar and facial area. Book IV//Moscow, 2005. — 460 p..
- Okeson J. The management of temporomandibular disorders and occlusion. Mosby, 2007
- Roth R. H. Functional occlusion for the orthodontist, part I // J. Clin. Orthod.- 1981,- 15. - P. 32-51.
- Available at: <https://americanboardortho.com/> Accessed November 05, 2018.