



CODEN [USA]: IAJ PBB

ISSN: 2349-7750

**INDO AMERICAN JOURNAL OF
PHARMACEUTICAL SCIENCES**<http://doi.org/10.5281/zenodo.1560631>Available online at: <http://www.iajps.com>

Research Article

**AN EXPERIMENTAL STUDY ON THE LAPAROSCOPIC
APPENDICECTOMY WITH SUPRAPUBIC CAMERA PORT**¹Saira Amin, ²Muhammad Waqas Saleem, ³Faiza Babar¹Lahore General Hospital Lahore²Mayo Hospital Lahore³Lahore General Hospital Lahore**Abstract:**

Objective: The purpose of this research work is to assess the findings of LA (Laparoscopic Appendectomy) with the utilization of the midline suprapubic camera port (SCP).

Methodology: The duration of this research work was from January 2017 of April 2018. All the patients who were undergoing surgical removal of the appendix with laparoscopy during the period of this study were the part of this research work. The analysis of the duration of the surgery, conversion of the surgery, problems and stay in the hospital carried out.

Results: Thirty-four were the total participants in which twenty-one were the male patients and thirteen were the female patients. The average age of the patients was 25.12 years. The average time of surgery was 54.39 minutes. Only 3 patients found necessary to change the method to open appendectomy whereas the infection of wound developed in only 2 patients. The average stay at the hospital was 1.29 days.

Conclusion: The findings of this study proved that LA (Laparoscopic Appendectomy) with the help of SCP is very preventive, safe & striking procedure.

Key Words: Surgical Removal, Infection of Wound, Cholecystectomy, Ergonomics, camera, Laparoscopic Exposure, Periumbilical, SCP.

Corresponding author:**Saira Amin,**Lahore General Hospital,
Lahore

QR code



Please cite this article in press Saira Amin et al., *An Experimental Study on the Laparoscopic Appendectomy with Suprapubic Camera Port.*, Indo Am. J. P. Sci, 2018; 05(11).

INTRODUCTION:

The surgical removal of the appendix is a very common general method of operation. Charles McBurney in the year of 1889 represented a testimony on early surgical interference in case of serious swollen appendix to the surgical society of the New York & just after 5 years he made the methods and elaborated McBurney's incision [1, 2]. Very 1st LA was encountered after one century in the year of 1983 by a gynaecologist, Kurt Semm from Germany [3]. Today, even after thirty-five years, the procedure of LA is not popular. Many early trails found fail to display the total advantages of this method, greater time of surgery, equal hospitalization duration & great danger of collection in the abdomen or after operation ileus with laparoscopic appendectomy overshadowed any betterment in the problems of wounds & healing duration or cosmesis. Recent research works show the inclination in the support of the laparoscopy, probably because of the enhancement of the laparoscopic exposure in the surgical training.

The available proof of decrease in the surgery time, early recovery & low rate of complications in the wound are in support of laparoscopy [4]. Various methods are elaborated by various authors for Laparoscopic appendectomy in respect to the placement of the port, managing the foundation of the appendix, separation of meso appendix & about the appendix removal [5-12]. About the placement of the camera port, the main disparity is the utilization of the site either periumbilical site or suprapubic site [6, 7, 13]. In this research work, we utilized the site of suprapubic port because it was concluded as safe [in the matters of ergonomics & cosmesis [5]. The

most frequent conducted surgery of laparoscopy is cholecystectomy; this method has benefit that three operational ports are placed 1 quadrant below. This is an early report of our practice with the utilization of the procedure of laparoscopic appendectomy.

METHODOLOGY:

Patients who underwent LA were the part of this research work. The duration of this research work was from January 2017 of April 2018. Patients were put on the surgical table with face upward & general anaesthesia was utilized in all the patients. A urinary catheter was put for the decompression of the bladder, removal of that catheter carried out in the end of the operation. The specialist and the camera operator were standing at the left side of the patient, facing towards the monitor which was lying at right side of table. Open hasson method used for the establishment of the pneumoperitoneum with the help of ten millimetres infraumbilical incision. A forward looking ten millimetres laparoscope was placed inside the cavity of abdomen & analytical laparoscopy carried out, then under the guidance another ten millimetres port was entered two centimetres on top of pubic symphysis in the midline & the telescope was moved to the site of suprapubic. Another five millimetres port was initiated in the right iliac fossa as shown in Figure-1.

Umbilical port & right iliac fossa port was in use for the right hand instrument and instrument of left hand respectively. Retraction & dissection carried out with the method of two handed. Endobags were in use for the elimination of fat appendix whereas thinner appendixes were eliminated with the help of reducer sleeve.

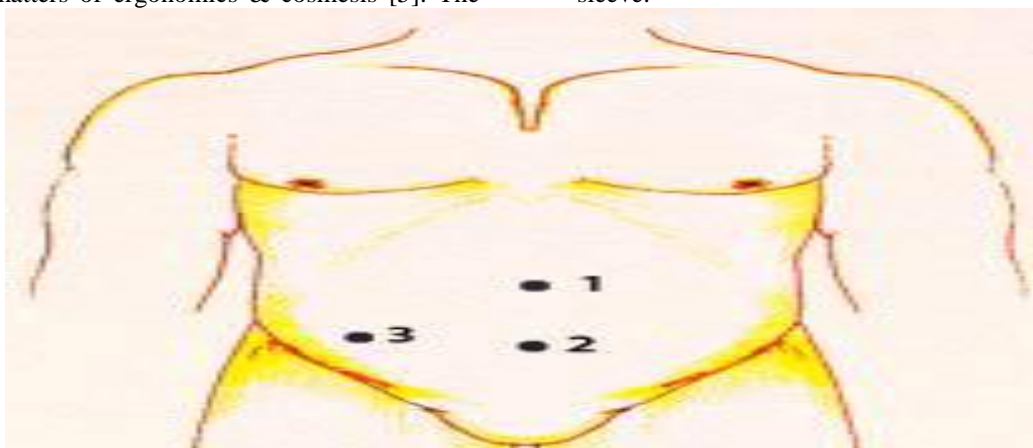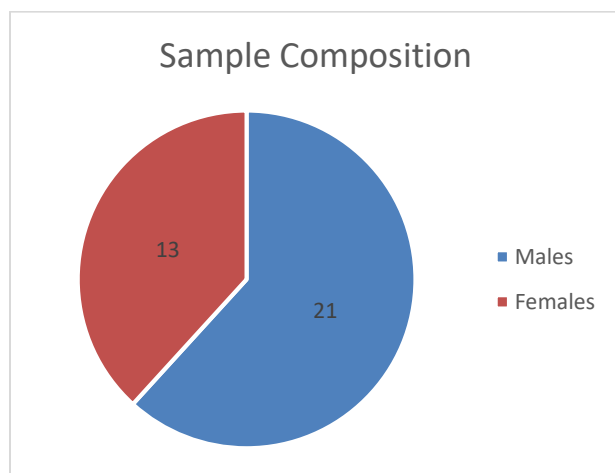


Fig-1: Port Placement

1. 10mm Right hand working port
2. 10 mm Camera port
3. 5 mm Left hand working port

RESULTS:

During the period of this research work, 34 faced LA with the utilization of the mentioned method, out of which 21 were the men and 13 were the female patients. The average age of the patients was 25.12 years. The range of the age of the patients was fifteen years to fifty-three years. The average duration of the surgery was 54.39 minutes. The range of the duration of the surgery was twenty-five minutes to two hours. After the exclusion of 3 patients whose method was changed to open procedure, the average duration of the surgery was 49.19 minutes. Open appendectomy carried out in 3 patients, gangrenous bases found in two patients & in the case of 3rd patient, appendix was entrenched in a very small size bowel mesentery and LA procedure was unable to tackle it. Infection of the wound developed in case of two patients which settled down with the help of concerning precautions. More than seventy-six percent patients got discharge from the hospital after twenty-four hours, six patients got discharge after two days and two patients got discharge after 3 days of the operation with an average stay of 1.29 days in the hospital.

**DISCUSSION:**

The fame of laparoscopic appendectomy has risen since its beginning but it is still away from getting the eminence of ideal standard. The benefits of laparoscopic appendectomy are very fast & low painful healing, less problems, better cosmesis & good evaluation of diseases of internal abdomen [14]. Various methods have been prescribed by different specialist to carry out the laparoscopic appendectomy [5-12]. The working place for the ports changes from the upper quadrant of right portion to the point of Mc Burney, inferior midline & left iliac fossa in ideal

operational & texts of laparoscopy [15-17]. The placement of the port gives better image of the lower caecum surface & the base of the appendix. It imitates the placement of the port in LA as 3 main ports are basically go 1 quadrant below and it is concluded to be in an ergonomic manner and cosmetically better by many researchers [6]. The experience decreases the operative time laparoscopic appendectomy [18]. The concluded average time for surgery varies from eighteen minutes as reported by Hussain [19] to one hundred and ten minutes [20]. The average time in this research work was 54.39 minutes. Mustafa Kamal has concluded the average surgery time as fifty-five minutes in a study carried out in Multan [21].

The change of the method to open appendectomy was needed in three patients due to some complications in the cases. Various case works concluded rate of conversion varying from less than one percent to more than twenty-one percent [22, 23]. Ng from Hong Kong utilizing the same method have concluded conversion rate of 8.7% in his study on seven hundred and ninety-five patients [5]. Conversion of the method increases the surgery duration & stay in the hospital & in this study the mean time of surgery for the converted patients was ninety minutes whereas with the exclusion of these 3 patients, the mean time of the surgery was 49.19 minutes. The most common causes of the conversion concluded in the subject are complicated anatomy & problematic swollen and painful appendix [24].

The average stay in the hospital was 1.29 days which was very similar to many others [18, 25]. Bennett confirmed the decrease in the duration of the hospital stay for laparoscopic appendectomy as compared to other methods [4]. Gilliam have displayed that laparoscopic appendectomy is a secure and effective [26]. Infection in the wound occurred in only two cases which is also similar with many authors [26, 27]. This infection was much lower than the infection caused by the open appendectomy [4, 29]. This is due to the method of the removal of appendix, as removal in the end bag or with the reducer sleeve prevents any exposure between the infected appendix and the new wound [21, 28, 30]. One of the demerits of the laparoscopic appendectomy is high occurrence of the formation of the abscess in the abdomen [4]. But no such type of complication formed in our patients.

CONCLUSION:

Although the amount of the participants is very less but the findings of the work are comparable to works of the particular field. The work found that LA with

the suprapubic port of the camera is very secure & striking procedure.

REFERENCES:

1. McBurney C. Experience with early operative interference in cases of disease of the vermiform appendix. *New York Med J* 1889;1:676-84.
2. McBurney C. The incision made in the abdominal wall in cases of appendicitis, with a description of a new method of operating. *Ann. Surg* 1894;20:38
3. Semm K. Endoscopic appendectomy. *Endoscopy* 1983;15:59-64.
4. Bennett J, Boddy A, Rhodes M. Choice of approach for Appendectomy: A Meta-analysis of open versus Laparoscopic Appendectomy. *Surg Laparosc Endosc Percutan Tech* 2007;17:245-55
5. Ng WT, Lee YK, Hui SK, Sze YS, Chan J, Zeng AGY, et al. An Optimal, Cost-effective Laparoscopic Appendectomy Technique for Our Surgical Residents. *Surg Laparosc Endosc Percutan Tech* 2004;14:125-9.
6. Ng WT. Port placement for laparoscopic appendectomy with the best cosmesis and ergonomics. *Surg Endosc* 2003;17:166-7.
7. Motson RW, Kelly MD. Simplified technique for laparoscopic appendectomy. *ANZ J Surg* 2002;72:294-5.
8. Shalaby R, Arnos A, Desoky A, Samaha AH. Laparoscopic Appendectomy in Children: Evaluation of Different Techniques. *Surg Laparosc Endosc Percutan Tech* 2001;11:22-7.
9. D'Souza FR, Anwar MA, Audisio RA, Memon MA. A simple and inexpensive method for laparoscopic appendectomy. *Surg Technol Int* 2007;16:93-6.
10. Aslan A, Karaveli C, Elpek O. Laparoscopic appendectomy without clip or ligature. An experimental study. *Surg Endosc* 2007;20:84-7.
11. Saad M. Fisherman's technique, introducing a novel method for using the umbilical port for removal of appendix during laparoscopic appendectomy. *Surg Laparosc Endosc Percutan Tech* 2007;17(5):422-4.
12. Hanssen A, Plotnikov S, Dubois R. Laparoscopic appendectomy using a polymeric clip to close the appendicular stump. *J Society Laparoscopic Surg* 2007;11(1):59-62.
13. Pedersen AG, Petersen OB, Wara P. Randomized clinical trial of laparoscopic versus open appendectomy. *Br J Surg* 2001;88:200-5.
14. Sweeny KJ, Keane FBV. Moving from open to laparoscopic appendectomy. *Br J Surg* 2003;90:257-8
15. Josloff RK, Zucker KA. Laparoscopic appendectomy. In: Zucker KA, ed. *Surgical laparoscopy*. Philadelphia: Lippincott Williams & Wilkins 2001;229-36.
16. Ferguson CM. Acute appendicitis. In: Morris PJ, Wood WC, eds. *Oxford Textbook of Surgery*. New York, Oxford University Press. 2000;1539-43.
17. Soybel DI. Appendix. In: Norton JA, Ballinger RR, Chang AE. eds. *Surgery: basic science and clinical evidence*. New York, Springer-Verlag 2001;647-67.
18. Ali A, Moser MA. Recent experience with laparoscopic appendectomy in a Canadian teaching centre. *Can J Surg* 2008;51(1):51-5.
19. Hussain A, Mahmood H, Singhal T, Balakrishnan S, El-Hasani S. Laparoscopic appendectomy in a district hospital: does the technique influence the outcome? *J Laparoendosc Adv Surg Tech A* 2008;18(2):204-8.
20. Long KH, Bannon MP, Zietlow SP. A prospective randomized comparison of laparoscopic appendectomy with open appendectomy: Clinical and economic analyses. *Surgery* 2001;129:390-400.
21. Kamal M, Qureshi KH. Laparoscopic versus open appendectomy. *Pak J Med Res* 2003;42:23-6
22. Konstantinidis KM, Anastasakou KA, Vorias MN, Sambalis GH, Georgiou MK, Xiarchos AG. A decade of laparoscopic appendectomy: Presentation of 1026 patients with suspected appendicitis treated in a single surgical department. *J Laparoendosc Adv Surg Tech A* 2008;18(2):248-58.
23. Paterson HM, Qadan M, DeLuca SM, Nixon SJ, Paterson-Brown S. Changing trends in surgery for acute appendicitis. *Br J Surg* 2008;95:363-8.
24. Hellberg A, Rudberg C, Enochsson L, Gudbjartson T, Wenner J, Kullman E, et al. Conversion from laparoscopic to open appendectomy: a possible drawback of the laparoscopic technique? *Eur J Surg* 2001;167(3):209-13.
25. Parveen S, Sarwar G, Saeed N, Channa GA. Laparoscopic versus open appendectomy as an elective procedure. *Med Channel* 2007;13(1):18-20.
26. Gilliam AD, Anand R, Horgan LF, Attwood SE. Day case emergency laparoscopic appendectomy. *Surg Endosc* 2008;22(2):483-6.
27. Tanaka S, Kubota D, Lee SH, Oba K, Matsuyama M. Effectiveness of laparoscopic approach for acute appendicitis. *Osaka City Med J* 2007;53(1):1-8.
28. Caravaggio C, Hauters P, Malvaux P, Landenne J, Janssen P. Is laparoscopic appendectomy an

- effective procedure? *Acta Chir Belg* 2007;107(4):368-72.
29. Pokala N, Sadhasivam S, Kiran RP, Parithivel V. Complicated appendicitis—is the laparoscopic approach appropriate? A comparative study with the open approach: outcome in a community hospital setting. *Am Surg* 2007;73(8):737-41.
30. Khan MN, Fayyad T, Cecil TD, Moran BJ. Laparoscopic versus open appendectomy: the risk of postoperative infectious complications. *J Society Laparoscopic Surg* 2007;11(3):363-7.