



CODEN [USA]: IAJ PBB

ISSN: 2349-7750

**INDO AMERICAN JOURNAL OF
PHARMACEUTICAL SCIENCES**<http://doi.org/10.5281/zenodo.1422653>Available online at: <http://www.iajps.com>

Research Article

**A STUDY ON THE CASES OF OBSTRUCTIVE JAUNDICE; THE
DIAGNOSTIC ACCURACY OF MRCP**¹Dr. Hina Hanif Mughal, ² Dr. Muhammad Usman Shahid, ³ Dr. Muhammad Zeeshan Khan¹Holy Family Hospital Satellite Town, Rawalpindi²RHC Renala Khurd, Okara³PIMS Hospital, Islamabad**Abstract:**

The main purpose of this study was to evaluate accuracy of magnetic resonance cholangiopancreatography (MRCP) diagnosis taking ERCP as gold standard in diagnosis of obstructive jaundice. A cross sectional validation study was done at the Department of Radiology, Holy Family Hospital Satellite Town Rawalpindi from July 2015 to May 2016. In the present study 80 cases of both male and female genders with age greater than 18 were considered. Those cases were enrolled in the study that had obstructive jaundice, whose diagnosis was made by discoloration (yellowing) of eyes for >1month and above 3mg/dl bilirubin level. MRCP using 1.5 tesla machine was performed followed by ERCP for confirmation of the findings and diagnosis of MRCP. IN both tests performed obstruction was labeled yes if more than 50% lumen is was diagnosed.

Corresponding author:

Dr. Hina Hanif Mughal,
Holy Family Hospital Satellite Town,
Rawalpindi

QR code



Please cite this article in press Hina Hanif Mughal *et al.*, *A Study on the Cases of Obstructive Jaundice; the Diagnostic Accuracy of MRCP.*, *Indo Am. J. P. Sci.*, 2018; 05(09).

INTRODUCTION:

One of the most recurrent and severe form of hepatobiliary disease is Obstructive jaundice. It can be intra or extra ductal mechanical blockage of obstructive jaundice can be caused by gallstones in the bile ducts, pancreatic and gallbladder cancer, bile ducts strictures, cholangitis, congenital malformations and pregnancy. Obstructive jaundice is linked with significant morbidity and mortality. Symptoms of jaundice which patients can have eyes discoloration (yellowing), itchiness all over the body, weight loss and vomiting. In obstructive jaundice correct and early diagnosis is extremely important so that its effects can be controlled at early stage. In the past decade's conventional test like USG (ultrasonography) and CAT scans with variable level of success have been used for diagnosis of obstructive jaundice.

However, these tests have some limitations like in CAT scan patients are exposed to radiations and requires an IV contrasts where as in case of USG, trained operator is required to perform the test. However, in recent times for the diagnosis of obstructive jaundice ERCP is set as gold standard. It is because of ERCP manipulation advantage by which not only obstructive jaundice is diagnosed but patient can also be relieved with it. But pancreatitis due to slipped gall stones is an unnecessary and is a well-studied complication of great concern. The data regarding the role of MRCP is insufficient and its precision in obstructive jaundice is changeable ranging from 80-100%. In this study 80 cases of male and females were randomly selected with age more than 20 years and cases were selected on the basis of conjugated bilirubin level above 3mg/dl and discoloration of Sclera for more than one month. By using 1.5 tesla machine MRCP was done. Obstruction of the lumen above 50% was labeled as

yes. Similar samples were when analyzed for obstruction using ERCP, similar criteria were used as mentioned above for MRCP.

Statistical analysis

SPSS-21 software was used for analysis of the data.

Chi-square test was applied and p value

above 0.05 was considered statistically significant.

METHODOLOGY;

Study design: it is a Cross sectional validation type of study.

Study Setting: Department of Radiology,

.....

Duration of Study: july2017 to may 2018

MATERIAL AND METHODS:

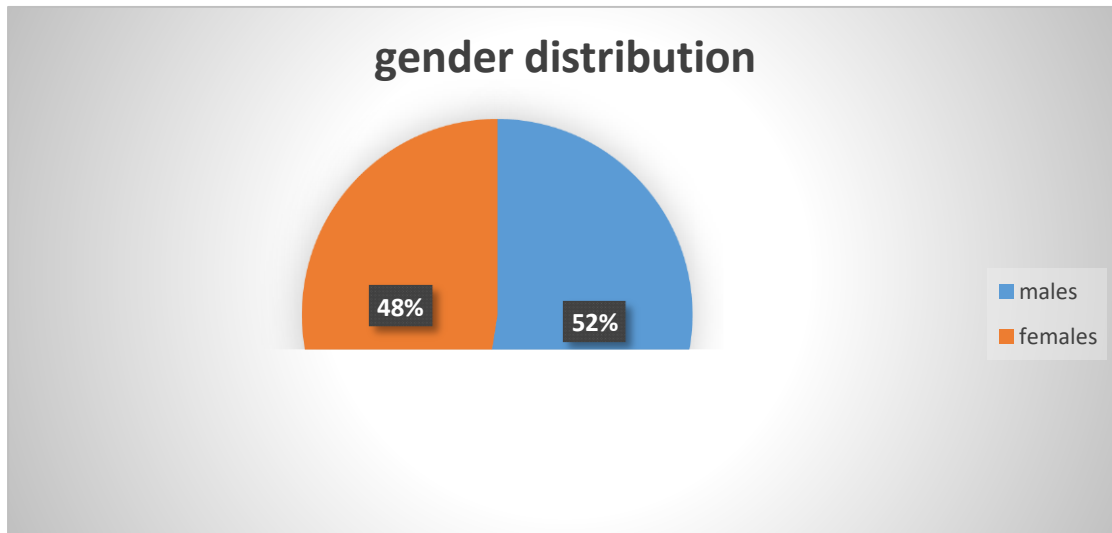
In our Study, 80 patients of both the genders aging more than 18 years were enrolled. The patients were enrolled who had obstructive jaundice, the yellowish discoloration of sclera for less than a month and conjugated bilirubin < 3mg/dl. Then MRCP was done of these patients using 1.5 tesla machine and obstruction was determined and labelled when it was more than 50% of the duct lumen. after that, ERCP was done for determining the size of obstruction and labelled positive when similar percentage was confirmed by ERCP. The data was analyzed by SPSS 21 and post stratification of effect modifiers; chi square was applied.

RESULTS:

In our study, total of 80 cases enrolled, out of which 42 (52.5%) were females patients and 38 (47.5%) were males patients with mean age 45.79±6.23 years. And the mean BMI Was recorded to be 28.98±5.16 as shown in table 01.

	Mean	Range
Age	45.79±6.23	18-75
Bmi	28.98±5.16	25-37
illness	3.82±0.61	1-6

Obstructive jaundice reported in 61 (95%) patients On the MRCP and 63 (98.33%) on the ERCP. The sensitivity of diagnosis of MRCP for the obstructive jaundice was recorded to be 96.8%, PPV was 96.8% and diagnostic accuracy was 96.79% with $p=0.01$



DISCUSSION:

Gall stones are notorious in obstructing the biliary tract, thus leading to pressure build up and secretions including bilirubin is retained. It is the most common cause of the obstruction, and can be of variable size, asymptomatic when the size is small and can result in partial or complete obstruction. They can be asymptomatic in nearly 5% of cases and the prevalence varies from 7-20% [1,2]. Although the CBD stones (common bile duct) may be asymptomatic or silent, and the development of complications like acute pancreatitis and cholangitis has association with increased morbidity and mortality rate. So, it is mandatory to detect and treat the CBD stones. The ERCP is quite a good technique diagnostically, but due to risks of acute pancreatitis, on-invasive test with good degree of accuracy must be used. In this present study, the obstructive jaundice was Reported to be in 57 (95%) of patients on MRCP and 59 (98.33%) of patients on ERCP. The sensitivity, PPV and diagnostic accuracy of MRCP in patients of obstructive jaundice was 96.8%, 96.8% and 96.79% respectively, with $p=0.01$. These results are in line with a study done by Mubarak et al, reporting that the diagnostic accuracy of MRCP in patients of obstructive jaundice was 80%, specificity 75%, positive predictive value 99% and negative predictive value 60%. Similar Findings were reported by a study done by Mumtaz N et al which showed that the diagnostic accuracy was in almost 100% of cases. The results of our study are in accordance with another study performed by Singh et al who found

The diagnostic accuracy of 100% while studying the patients of obstructive jaundice.8 El- Sayed EY et al in Egypt did a study with similar protocols and the diagnostic accuracy of MRCP was found to be about 86% only.

CONCLUSION:

MRCP shows significant better results in terms of diagnostic accuracy in cases of obstructive jaundice while taking the ERCP technique as gold standard.

REFERENCES:

1. Nadkarni KM, Jahagirdar RR, Kazgi RS, Pinto AC, Bhalerao RA. Surgical Obstructive Jaundice. *J Postgrad Med.* 1981;24(4):33-9.
2. Hakansson K, Ekberg O, Hakansson HO, Leander P. MR and ultrasound in screening of patients with suspected biliary tract disease. *Acta Radiol.* 2002; 43:80-86.
3. Zandrino F, Benzi L, Ferretti ML. Multislice CT cholangiography without biliary contrast agent: technique and initial clinical results in the assessment of patients with biliary obstruction. *Eur Radiol.* 2002; 12:1155-61.
4. Sheridan MB. Endoscopic retrograde cholangiopancreatography should no longer be used as a diagnostic test: the case in favour. *Digest Liver Dis.* 2002; 34:370-4.
5. Griffin N, Charls-Edwards G, Grant LA. Magnetic resonance. cholangiopancreatography: the ABC of MRCP insights. *Imaging.* 2012; 3:11-21.

6. Mubarak A, Ishtiaq A, Waseem A, Amjad S, Mujahid H, Zaigham A. Diagnostic accuracy of magnetic resonance cholangio-pancreatography in evaluation of obstructive jaundice. *J Pak Med Assoc.* 2012;62(10):1053-6.
7. Ali M, Akhtar W, Sattar A, Hussain M, Abbas Z. Diagnostic accuracy of magnetic resonance cholangio-pancreatography in evaluation of obstructive jaundice. *J Pak Med Assoc.* 2012;62(10):1053-6.
8. Singh A, Mann HS, Thukral CL, Singh NR. Diagnostic accuracy of MRCP as compared to USG/CT in patients with obstructive jaundice. *J Clin Diag Res.* 2014;8(3):103-07.
9. Mumtaz N, Akram MH. Comparison of magnetic resonance cholangiopancreatography and endoscopic retrograde cholangiopancreatography in hepatobiliary disorders. *Pak Arm Force Med J.* 2011;30(2):21-36.
10. ElSayed EY, El-Maati AA, Mahfouz M. Diagnostic value of magnetic resonance cholangiopancreatography in cholestatic jaundice. *Egypt J Rad Nuc Med.* 2013; 44:137-46.