CODEN [USA]: IAJPBB ISSN : 2349-7750

INDO AMERICAN JOURNAL OF
PHARMACEUTICAL SCIENCES
SJIF Impact Factor: 7.187
http://doi.org/10.5281/zenodo.4430131

Avalable online at: http://www.iajps.com *Research Article*

EFFICACY OF BALLOON ATRIAL SEPTOSTOMY AS AN EMERGENCY PALLIATIVE PROCEDURE IN THE NEONATES WITH CONGENITAL CYANOTIC HEART DEFECTS

[1]Dr Hina Lodhi, [2]Dr Asad ur Rehman, [3]Dr Tayyaba Roshni

[1]Nishtar Medical College and University, Multan., [2]Mohtarma Benazir Bhutto Shaheed Medical College, Mirpur, AJK., [3]Nishtar Medical College and University, Multan.

Article Received: November 2020 **Accepted:** December 2020 **Published:** January 2021

Abstract:

Objective: *Balloon atrial septostomy (BAS) is a life-saving emergency palliative procedure in the neonatal period. Data from developing countries is limited. We describe our experience with BAS over the last three years.*

Methods: *This study was held in the Pediatric Cardiac surgery department of Nishtar Hospital, Multan for three years duration from December 2017 to December 2020. 158 patients underwent BAS. We analyzed their procedural and postoperative data, excluding patients with accompanying problems, e.g., sepsis, birth asphyxia, prematurity.*

Results: *158 patients underwent BAS. 142 were male and 16 females. The mean age was 20 days (range 1-105 days). The average weight was 3 kg (range 2.1 - 5.5 kg). The cutaneous saturation before the procedure was 59% (30-80%) and it increased to 80% (80-90%) after the procedure. 88 patients had received prostaglandin infusion prior to surgery. All of them were subsequently successfully weaned from prostaglandins. The procedure was completely echocardiographically controlled in 8 patients. In the rest, both fluoroscopy and echo were used. In 149 patients, the procedure lasted less than half an hour. In 9 patients, the procedure was technically difficult and lasted over half an hour. There was one mortality directly related to the procedure. The mean hospital stay was 48 hours after the procedure. Transient arrhythmias (supraventricular tachycardia, bradycardia) occurred in 7 patients. Three patients had transient apnea. No patient experienced balloon deflation failure.*

Conclusion: *A BAS can be conducted safely and effectively. It is an integral part of the management of conditions such as intact septal pulmonary atresia, TAPVC, TGA with intact septum, where atrial septum is restrictive. In these patients, BAS should be performed as the first step in treatment.*

Key words: *Balloon atrial septum, Transposition of great arteries with an intact ventricular septum. Atrial septum.*

Corresponding author:

Dr Hina Lodhi

Nishtar Medical College and University, Multan.

QR code

Please cite this article in press Hina Lodhi et al, ***Efficacy Of Balloon Atrial Septostomy As An Emergency Palliative Procedure In The Neonates With Congenital Cyanotic Heart Defects.,*** *Indo Am. J. P. Sci, 2021; 08(1).*

INTRODUCTION:

Balloon atrial septostomy (BAS) introduced by Rashkind and Miller is a life-saving procedure and one of the few indications for emergency catheterization in infants. Carried out carefully with attention to detail, the procedure carries little risk. It is indicated in all those congenital cyanotic heart defects in which inter-atrial communication is limited and survival depends on the inter-atrial mixing of the systemic and pulmonary circulation, e.g., transposition of large arteries with an intact ventricular septum, tricuspid atresia, total anomalous venous drainage, etc. (TAPVC) BAS, by enlarging the defect of the atrial septum, results in improved mixing and increased arterial saturation. Atrial balloon septum (BAS) is a lifesaving palliative procedure in the neonatal period. It has the potential to dramatically improve the infant's hemodynamic and symptomatic status. A BAS should be performed where appropriate to stabilize the patient. Data from developing countries is limited. We describe our experiences with the BAS of the Pediatric Cardiology and Cardiac Surgery Department.

METHODS:

This study was held in the Pediatric Cardiac surgery department of Nishtar Hospital, Multan for three years duration from December 2017 to December 2020. 158 patients underwent BAS. Two were diagnosed with pulmonary atresia with an intact ventricular septum, one patient had hyper cardiac TAPVC. The remaining patients were diagnosed with TGA with an intact ventricular septum (n = 155). All of these patients had restrictive inter-atrial communication. We analyzed their procedural and postoperative data, excluding patients with accompanying problems, e.g. sepsis, birth asphyxia, prematurity. We included patients with an additional patent ductus arteriosus in our study. We noted the saturation measured with pulse oximetry before and after the procedure, and the need to continue prostaglandin treatment and support breathing after septostomy. We searched for complications related to the procedure, including lower limb heart rate and temperature. Post-septostomy tear size was accurately measured by transthoracic echocardiography.

Procedural Details:

BAS can be performed both under echo control and in blood. We used to combine both techniques. After venous access through the femoral vein was secured, the 2cc ZMed septostomy balloon catheter was inserted into the right atrium and then into the left atrium through the patent foramen ovale. The balloon was fully inflated and then pulled back into the right atrium, causing the atrial septum to rupture. The jerk should not be too strong, otherwise it may injure the inferior vena cava. This maneuver may be repeated two to three times until resistance is encountered when pulling out a fully inflated balloon. Immediately after the procedure, there should be a marked improvement in the patient's satiation and clinical condition.

RESULTS:

158 patients underwent BAS. 142 (89.8%) are men, while the rest are women. Their mean age was 20 days, ranging from 1 to 105 days. Their average weight was 3 kg and ranged from 2.1 to 5.5 kg (table-1).

TABLE 1: Summary of Patients procedural and post procedural data (n=158)

Characteristic	Mean	Range
Weight (kilograms)	03	2.1-5.5
Age (days)	20	1-105
Procedural time (minutes)	30	10-180
Duration of hospital stay (hours)	48	1-144

All patients were on time. 155 patients had TGA with an intact septum. Two patients had pulmonary atresia with an intact ventricular septum; one patient had complete abnormal pulmonary vein drainage. All of these patients had restrictive atrial communication (<2 mm). The saturation of the skin in the air before the procedure was 59% (30–80%) and increased to 80% (60–90%), with an average increase in saturation after the procedure by 20%. 88 patients had received prostaglandin infusion prior to surgery. All of them later succeeded in rejecting prostaglandin. The procedure was completely echocardiographically controlled in 8 patients. In the rest, both fluoroscopy and echo were used. In 149 patients (94%), the procedure lasted less than half an hour. In 9 patients (5.6%) the procedure was

technically difficult and lasted over half an hour. The mean operative time was 30 minutes (10-180 minutes). The size of the tear formed in the atrial septum was 6 mm (2.6 to 8 mm). The mean length of hospital stay was 48 hours after surgery (from 1 hour to 6 days). Transient arrhythmias (supraventricular tachycardia, bradycardia) occurred in 7 (4.4%) patients. Three (1.8%) patients had apnea during the procedure which responded to ambu bagging for several minutes. There was one (0.6%) mortality directly related to the procedure (Table 2).

TABLE 2: Complications of procedure

Characteristic	Number	percentage
Transient arrhythmia	7	4.4
Transient apnea	3	1.8
mortality	1	0.6

We found no balloon deflation failure in any patient.) In a patient with TAPVC, corrective surgery (pulmonary veins redirection) was performed two months later. Patients with pulmonary atresia with an intact septum are regularly monitored for right ventricular growth. Of the 155 TGA cases, 104 patients were under 4 weeks of age and their left ventricle was still adequate in size. 86 patients underwent surgery to change the artery. 12 patients were executed and 6 patients went to Stenting's surgery. 56 patients reported with left ventricular regression. The rest are awaiting surgery (Figure 1).

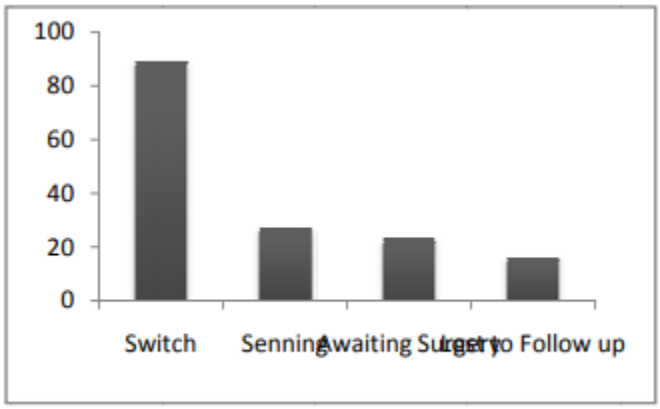

Fig 1: Follow up

DISCUSSION:

Along with the improvement of conditions in health care facilities, children with congenital heart defects are detected early and referred to pediatric cardiology departments for proper diagnosis and treatment. Congenital heart disease (CHD) that occurs in newborns is usually serious and requires prompt treatment. In many cases, survival of CHD depends on intracardiac mixing, eg, TGA with an intact septum, septal intact lung atresia, total pulmonary venous abnormal junction (TAPVC), and tricuspid atresia. In such patients, the restricted atrial opening can lead to shock, cardiovascular collapse, and even death if left untreated. Urgent balloon atrial septostomy improves mixing and helps newborns undergo surgery. Cyanotic newborns suspected of having cardiac damage should be transferred to an intensive care unit in a third-degree pediatric ward. Prostaglandin infusion should be started to maintain ducts patency. Many of these patients arrive late, ie after the first month of life, when corrective surgery cannot be offered immediately. BAS helps stabilize these patients and can later be referred for two-step surgery or for physiological correction. In our experience, we have performed a BAS on a patient with epidural TAPVC. The aforementioned patient was 4 months old and came to us with a circulatory collapse. Echo revealed that his left ventricular exit depended on an atrial septal defect that had been restricted. BAS was performed and inter-atrial communication expanded. The patient stabilized immediately after the procedure. Corrective surgery (pulmonary veins redirection) was performed two months later. BAS is technically considered easier in

newborns under 3 weeks of age because the primum septum is thin. However, in our experience, an experienced operator can also easily perform a BAS on older patients. During the entire procedure, patients were carefully monitored for vital signs, electrocardiography and oxygen saturation. Very few patients experienced complications. Transient arrhythmias occurred in 7 patients, and only two of them required antiarrhythmic drugs. The rest spontaneously returned to sinus rhythm. Two patients developed apnea that responded immediately to ambu bagging. There was one mortality directly related to the procedure that occurred early in our experiment. Three patients developed ICU cross-infection and were left in the hospital for more than two days. All others were held in the intensive care unit for 48 hours pending observation, and then discharged. There has not yet been any research on this at national level. We compared the data with similar surveys in our part of the world as well as from developed countries and found a comparable result.

CONCLUSION:

We come to the conclusion that BAS can be safely and effectively used in children with excellent results. In addition, it is an integral part of the management of conditions such as intact septal pulmonary atresia, TAPVC, TGA with an intact septum, in which the intercurrent septum is restrictive. In these patients, BAS should be performed as the first step in treatment.

REFERENCES:

1. Critser, Paul J., Patrick D. Evers, Eimear McGovern, Michelle Cash, and Russel Hirsch. "Balloon atrial septostomy as initial therapy in pediatric pulmonary hypertension." *Pulmonary Circulation* 10, no. 4 (2020): 2045894020958970.
2. Buca, Danilo, Per Winberg, Giuseppe Rizzo, Asma Khalil, Marco Liberati, Alexander Makatsariya, Francesca Greco, Luigi Nappi, Ganesh Acharya, and Francesco D'Antonio. "Prenatal risk factors for urgent atrial septostomy at birth in fetuses with transposition of the great arteries: a systematic review and meta-analysis." *The Journal of Maternal-Fetal & Neonatal Medicine* (2020): 1-9.
3. Liang, Kae-Woei, and Kuo-Yang Wang. "Balloon atrial septostomy and transition of subcutaneous to intravenous prostacyclin infusion for rescuing advanced right heart failure in idiopathic pulmonary arterial hypertension: a case report." *European Heart Journal-Case Reports* (2020).
4. Zayegh, Amir, Michael Stewart, Carmel Delzoppo, and Bennett Sheridan. "Improving transport time for babies with antenatally diagnosed transposition of the great arteries reduces the need for ECMO." *Journal of Perinatology* (2020): 1-6.
5. Hautala, Johanna, Mika Gissler, Annukka Ritvanen, Emmi Helle, Jaana Pihkala, Ilkka P. Mattila, Tommi Pätilä et al. "Perinatal and perioperative factors associated with mortality and an increased need for hospital care in infants with transposition of the great arteries: A nationwide 11-year population-based cohort." *Acta obstetricia et gynecologica Scandinavica* 99, no. 12 (2020): 1728-1735.
6. Kang, Sok-Leng, Edgar Jaeggi, Greg Ryan, and Rajiv R. Chaturvedi. "An Overview of Contemporary Outcomes in Fetal Cardiac Intervention: A Case for High-Volume Superspecialization?." *Pediatric Cardiology* (2020): 1-7.
7. Ugurlucan, Murat, Yahya Yildiz, Didem Melis Oztas, Senay Coban, Metin Onur Beyaz, Gizem Sari, Mustafa Ozer Ulukan et al. "Congenital cardiac interventions during the peak phase of COVID-19 pandemics in the country in a pandemics hospital in Istanbul." *Cardiology in the Young* 30, no. 9 (2020): 1288-1296.
8. Fraser Jr, Charles D., Martin A. Chacon-Portillo, Andrew Well, Rodrigo Zea-Vera, Ziyad Binsalamah, Iki Adachi, Carlos M. Mery, and Jeffrey S. Heinle. "Twenty-Three-Year Experience With the Arterial Switch Operation: Expectations and Long-Term Outcomes." In *Seminars in Thoracic and Cardiovascular Surgery*. WB Saunders, 2020.
9. Galantowicz, Mark. "Hybrid Procedures: A Surgeon's Viewpoint on the Next 10 Years." *Pediatric Cardiology* (2020): 1-8.
10. Loomba, Rohit. "Creating a Systematic Framework Approach to Congenital Heart Disease Comprehension and Management–A Primer for the Cardiac Intensive Care Unit Provider." *Available at SSRN 3593314* (2020).
11. Gorbachevsky, Sergey V., Anton A. Shmalts, Gulomjon M. Dadabaev, Nasirullo A. Nishonov, Manolis G. Pursanov, Vladimir A. Shvartz, and Sergey B. Zaets. "Outcomes of Atrioseptostomy with Stenting in Patients with Pulmonary Arterial Hypertension from a Large Single-Institution Cohort." *Diagnostics* 10, no. 9 (2020): 725.
12. Nathan, Meena, Felicia L. Trachtenberg, Maria I. Van Rompay, William Gaynor, Kirk Kanter, Richard Ohye, Emile A. Bacha et al. "The pediatric heart network residual lesion score

study: design and objectives." *The Journal of thoracic and cardiovascular surgery* 160, no. 1 (2020): 218-223.

13. Kiper, Carmen, Clifford L. Cua, Peter Baker, and Patrick McConnell. "Mitral Valve Replacement in Pediatrics Using an Extracellular Matrix Cylinder Valve: A Case Series." *Pediatric Cardiology* 41, no. 7 (2020): 1458-1465.
14. Desai, Suneel Ramesh, and Nian Chih Hwang. "Strategies for left ventricular decompression during venoarterial extracorporeal membrane oxygenation-a narrative review." *Journal of cardiothoracic and vascular anesthesia* 34, no. 1 (2020): 208-218.
15. Trucco, Sara M., and Jacqueline Kreutzer. "Cardiac Catheterization." In *Critical Care of Children with Heart Disease*, pp. 41-59. Springer, Cham, 2020.