CODEN [USA]: IAJPBB ISSN : 2349-7750

INDO AMERICAN JOURNAL OF
PHARMACEUTICAL SCIENCES

SJIF Impact Factor: 7.187
http://doi.org/10.5281/zenodo.4658025

Avalable online at: http://www.iajps.com *Research Article*

EVALUATION OF THE EFFECT OF USING MAGNESIUM SULFATE IN PERIBULBAR BLOCK FOR CATARACT SURGERY

Isam H Gaddaf Eldam[1], Ayman Salah Eldeen Abdelsalsm[2], Ibrahim Ahmed Ali Werfally[3], Gumma Almusmary [4], Awad M Alhasnony [5], Osama H. Aldeeb[6]

[1] Suhil El-Atrash Hospital and Benghazi Medical Center (BMC), Benghazi -Libya.
[2] Department of Anesthesia and Surgical ICU., Faculty of Medicine, Tobruk University, Tobruk -Libya.
[3]Department of Anesthesia and Surgical ICU, Faculty of Medicine, Benghazi University, Benghazi –Libya.
[4]Department of Ophthalmology, Faculty of Medicine, Tobruk University, Tobruk -Libya.
[5]Department of Biochemistry, Faculty of Medicine, Tobruk University, Tobruk –Libya.
[6]Department of Biochemistry, Faculty of Medicine, Omar Almokhtar University, Elbeida - Libya.

Article Received: February 2021 **Accepted:** February 2021 **Published:** March 2021

Abstract

Background: *Magnesium Sulfate has been used along with local anesthetics in different regional blocks and found to be effective in decreasing the time of onset of the block and increasing the duration of the block.*

Objective: *To evaluate the effect of addition of Magnesium Sulfate to Lidocaine on the time of onset of the sensory block, the globe and lid akinesia for peribulbar block in cataract surgeries.*

Patients and Methods: *Sixty patients with American Society of Anesthesiologists physical status I to II (ASA I & II) undergoing cataract surgery under peribulbar block were included in this study. Patients were randomized into two groups 30 patients each:*

Group I (Control group): *patients received a peribulbar block using a mixture of 5ml Lidocaine 2% and 1ml normal saline 0.9% .*

Group II (magnesium group): *patients received a peribulbar block using 5ml Lidocaine 2% and Magnesium Sulfate 10% (50mg) diluted in 1 ml normal saline 0.9%.*

The onset of loss of corneal sensation, globe and lid akinesia and complications were observed and recorded.

Results: *Patients received Magnesium Sulfate showed significantly rapid onset of complete loss of corneal sensation ($P = 0.036$), and significantly rapid onset of partial and complete lid and globe akinesia ($P < 0.001$) and ($P < 0.001$) respectively.*

Conclusion: *Addition of 50 mg of Magnesium Sulfate to the Lidocaine for peribulbar block decreases the onset of sensory block and akinesia without any obvious side effect.*

Keywords: Magnesium Sulfate , Peribulbar Block , Cataract

Corresponding author:
Isam H Gaddaf Eldam *,
Suhil El-Atrash Hospital and Benghazi Medical Center (BMC), Benghazi -Libya.

QR code

Please cite this article in press Isam H Gaddaf Eldam et al., ***Evaluation Of The Effect Of Using Magnesium Sulfate In Peribulbar Block For Cataract Surgery.,*** *Indo Am. J. P. Sci, 2021; 08(03).*

INTRODUCTION:

Progression in phacoemulsification techniques for cataract surgery [1-2] has also led to inevitable changes in the delivery of accompanying anesthesia from general to local modalities i.e. retrobulbar, peribulbar, Sub-Tenon's and topical anesthesia. [3-4]
General anesthesia is preferred for complicated intra-capsular cataract extraction (ICCE) surgery as this technique involves significant manipulation of the eye, and requires several corneal sutures to provide a watertight wound. Extra-capsular cataract extraction (ECCE) [5,6-7] also requires a large corneal incision, but there was a trend towards local anesthesia such as retrobulbar, which allows quicker patient recovery, and thus facilitated day-case surgery. [8-9] With the introduction of the foldable intraocular lens (IOL) [10], phacoemulsification and small-incision surgery has developed. [5,10-11] Initially, this was performed via a scleral tunnel and required sutures, thus retrobulbar and peribulbar anesthesia were preferred. [12,13] With the advent of small, stepped, and self-sealing corneal incisions, very little manipulation is required, and this allowed the use of Sub-Tenon's[14-15] and topical anesthesia.[12,16-17]

Regional anesthesia is a preferred technique for ophthalmic surgery. It is safe, inexpensive and provides efficient ocular anesthesia for ophthalmic surgery. Among regional blocks, peribulbar block is safer in comparison to retrobulbar block due to a lesser incidence of serious complications such as brainstem anesthesia, globe perforation, and retrobulbar hemorrhage. [18] However, the development of ocular akinesia with peribulbar block takes longer time in comparison to retrobulbar block, and the occurrence of inadequate analgesia is also more frequent in peribulbar block. [19,20]

In order to enhance the onset of akinesia and increased tissue diffusion, additives like Hyaluronidase [21], Adrenaline [22], Clonidine [23], Corticosteroids [24], Sodium bicarbonate[25] and neuromuscular blocking agents have been used in peribulbar block. These agents are also not devoid of side-effects like allergic reaction, bradycardia, sedation, dryness of mouth, systemic neuromuscular blockade, etc. Up to now, no one adjuvant is ideal for peribulbar block. (26,27,28)

Magnesium is a physiological calcium channel blocker and noncompetitive antagonist of N-methyl-D-aspartate (NMDA) receptors. [29] It has been used with a local anesthetic (LA) solution in different regional anesthesia technique to decrease the onset time of block and to increase the quality and duration of anesthesia.[30,31,32,33,34]

PATIENTS AND METHODS:

This study was carried out at Suhil-Elatrash hospital and Benghazi Medical Center (BMC) ,on 60 adults patients during the period from July 2017 to May 2018

Inclusion criteria:

- Axial eye length (18-25mm),
- American society of anesthesiologist's physical status (ASA) I and ASA II.

Exclusion criteria:

- Patient with ASA III and above
- Coagulation disorders
- High myopia more than 28mm
- Local infection(staphyloma)
- Marked uncontrolled tremors as parkinsonian head tremors
- Anatomical abnormalities or pre-existing extra-ocular muscle palsy
- Known or suspected allergies or sensitivity to amide local anesthetics.

The patients were divided into two groups (30 patients each):

Group I (Control group): Patients received a peribulbar block using a mixture of 5ml Lidocaine 2%, 1ml normal saline 0.9%.

Group II (Magnesium group): Patients received a peribulbar block using 5ml Lidocaine 2%, Magnesium Sulfate 10% (50mg) diluted in 1 ml normal saline 0.9%.

All patients in both groups will receive the same volume of local anesthetics mixture. The eye was prepared with a 5% povidone iodine solution.

Peribulbar anesthesia was done through single transcutaneous inferolateral injection technique using a 25-gauge, 25 mm bevel disposable needle. Patients were asked to maintain the eye in the primary position. The injection site was identified at the junction of the lateral one-third and medial two-third of the inferior orbital rim in the inferotemporal quadrant. The needle was advanced in an anteroposterior, slightly medial, and cephalad direction. After aspiration, the anesthetic solution was injected in approximately 30 seconds; the local anesthetic was injected until the presence of a complete drop and fullness of the upper eyelid. Slight external manual pressure with of 4-5 layers of gauze piece was applied over the eye immediately after injection for 5 minutes to promote the spread of local anesthetics and softening of the globe.

Corneal sensation: Was evaluated using cotton wick at 1, 3, 5,10,15 and 20 minutes till the onset of anesthesia, it will be assessed on 0-2 scale, were zero= no anesthesia, 1=partial but acceptable anesthesia and 2=complete anesthesia.

Akinesia extra-ocular muscles: Were evaluated before blocking, then 1,3,5,10,15 and 20 minutes after the block in all four directions using 3-point scale for each direction. Were zero = complete akinesia, 1=limited movement and 2= normal movement.

Akinesia of orbicularis muscle (eye lid): Were also evaluated before blocking then 1,3,5,10,15 and 20 after the block till the onset of anesthesia using 3-points scale, were zero = complete akinesia, 1= partial movement in either or both eyelid margins and 2=normal movement in either or both eyelid margins (Table 1).

Optimal time to start the surgery was defined as presence of corneal anesthesia together with the total ocular movement score ≤ 1 and eyelid squeezing score of zero.

Table 1: Three points scaling system for onset of peribulbar block

I.	***Corneal sensation***
	0 = no anesthesia 1 = partial but acceptable anesthesia 2 = complete anesthesia
II.	***Akinesia of extra-ocular muscles:***
	0 = complete akinesia 1 = limited movement 2 = normal movement
III.	***Akinesia of orbicularis muscle:***
	0 = complete akinesia 1 = partial movement in either or both eyelid margins 2 = normal movement in either or both eyelid margins.

Statistical methods:
Analysis was done with IBM SPSS 23.0. For monovariate analysis chi square and t test (or alternatively Mann Whitney U test for non-normally distributed variables). All results were considered statistically significant when ($P \leq 0.05$)

RESULTS:

Sixty patients were included in the study [28 males (46.7%) and 32 females (53.3%) and their age ranged from 43 to 87 years and the mean was 61.47±12.063

-Corneal sensation:

-Partial loss of corneal sensation:

Time to experience partial loss of sensation ranged from 0 to 10 minutes (mean was 3.37± 2.64 minutes) .

Group I mean time was 3.77 ± 3.16 minutes, while **group II** mean was 2.97 ±1.97 minutes with no significant difference detected between the studied groups ($P = 0.141$) .(Figure:1)

-Complete loss of corneal sensation:

Complete loss of sensation time ranged from 3 to 15 minutes (the mean was 6.8 ±4.47 minutes). (Figure :2)

Group I mean time was 8.1 ±4.92 minutes while **group II** mean time was 5. ±3.61 minutes with statistically significant difference ($P = 0.036$).(Figure :2)

- Motor akinesia:

- Partial akinesia

Time to partial akinesia ranged from 2 to 10 minutes (mean was 4.42 ±2.5 minutes).

Group I mean time was 5.9 ±2.4 minutes while **group II** mean time was 3.93 ±1.55 minutes with statistically significant difference ($P< 0.001$). (Figure: 4)

- Complete akinesia

Complete motor akinesia time ranged from 3 to 20 minutes. (mean was 9.5 ±5.24 minutes). (Figure :5)

Group I mean time was 13 ±3.37 minutes while **group II** mean time was 5.97 ±4.35 minutes with statistically significant difference (*P*< 0.001)

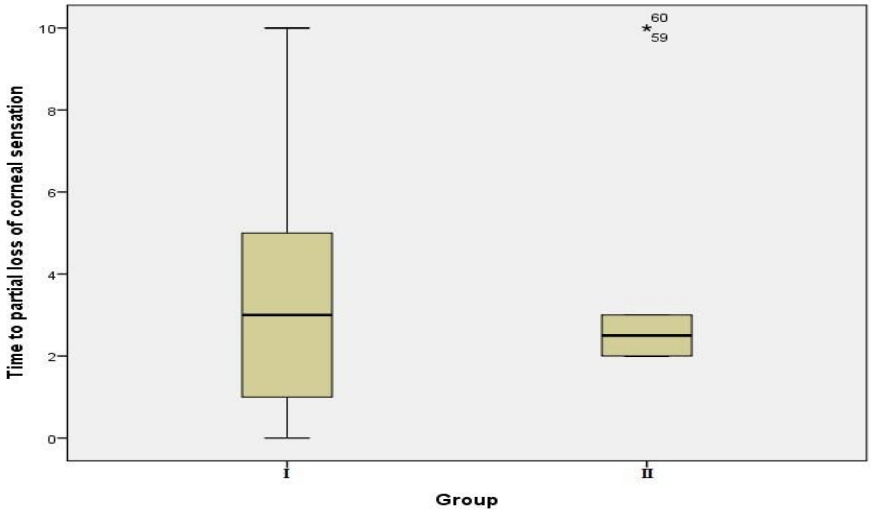

Figure (1): Comparison between two groups according to time to partial loss of corneal sensation

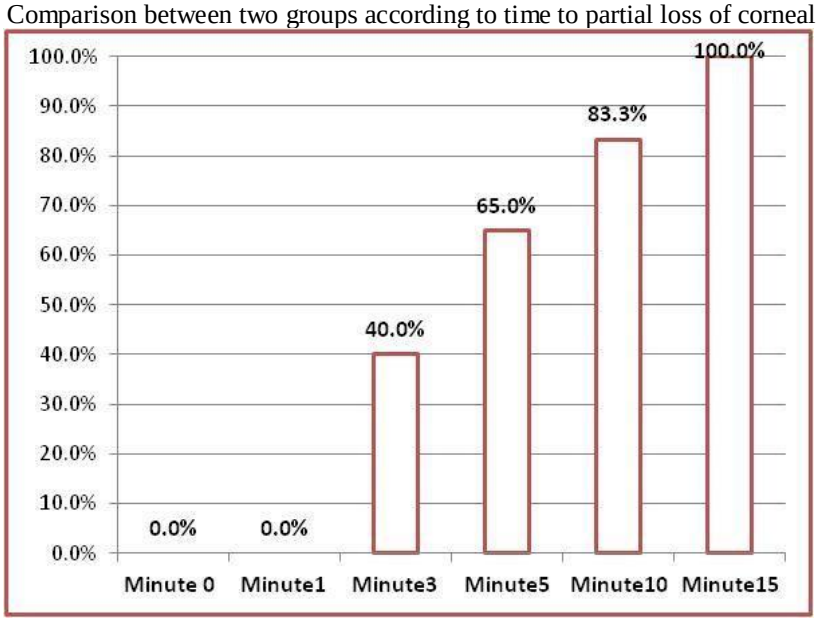

Figure (2): Distribution of cases according to onset of complete loss of corneal sensation

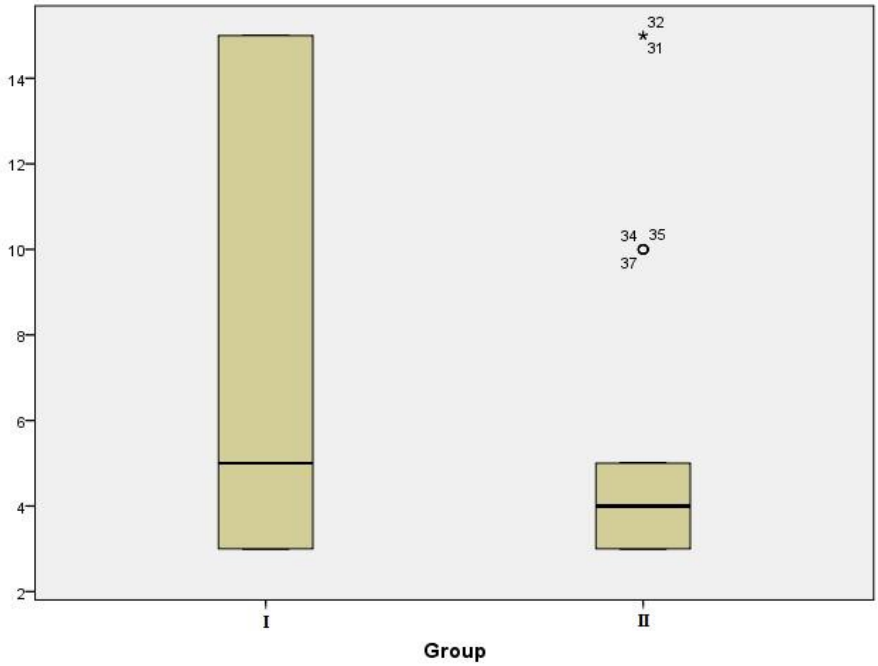

Figure (3): Parameters of time to complete loss of corneal sensation

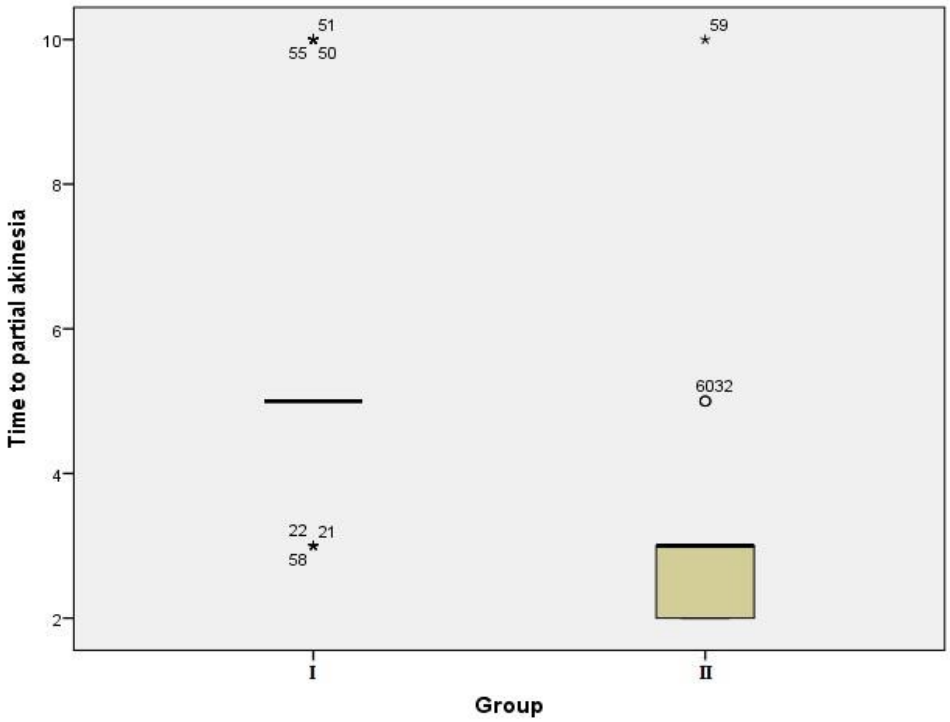

Figure (4): Parameters of time to partial akinesia

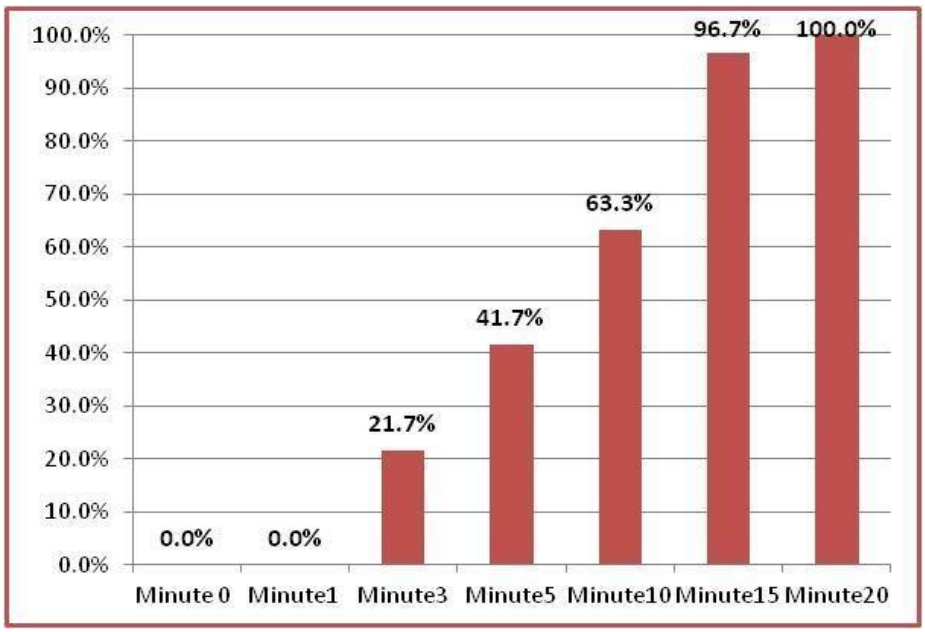

Figure (5): Distribution of cases according to onset of complete akinesia

DISCUSSION:

Peribulbar block is commonly used for different ophthalmic surgeries. It is safe, inexpensive, and provides excellent anesthesia and akinesia.[35]

The time for onset of akinesia with peribulbar block is much longer in comparison to retrobulbar block, [19] which may lead to a delay to start the surgery. The incidence of inadequate analgesia is also more frequent with peribulbar block. [19]

It has become a common practice to use adjuvant drugs to enhance the onset and prolong the duration of the block, because no drug has yet been identified that specifically inhibits nociception without associated side effects.[36]

Research continues concerning different techniques and drugs that could provide better anesthesia and akinesia, one of these drugs is Magnesium Sulfate.[29] Studies evaluated its effect as an additive to local anesthetics in different regional techniques e.g.: Intrathecal as an adjunct to LAs in pre-eclamptic patients undergoing cesarean section.[37] epidural as an adjuvant to Bupivacaine in elective cesarean section[31], and pre-incisional as local infiltration in patient undergoing hysterectomy [33], also it has been used as an adjuvant to Prilocaine in axillary brachial plexus block [34] and as an adjuvant to Lidocaine for IVRA.[38]It improves the quality of the anesthesia, increase duration of analgesia and hastens onset of the block in all the above studies.

In the current study Magnesium Sulfate was used as an adjuvant with Lidocaine 2% solution in peribulbar block to evaluate the effect of Magnesium Sulfate 50mg as an adjuvant compared to standard technique.

The study investigated the onset of sensory block (loss of corneal sensation) and degree of globe and lid akinesia (onset of the block).

The onset of sensory block (loss of corneal sensation) , globe and lid akinesia was statistically faster in the Group II (Magnesium group) as compared to the Group I (control group) in the first 10 min after the block. At 15 min complete loss of corneal sensation were seen in 100% of cases in both groups, and at 20 min complete akinesia were observed in 100% of cases in both groups.

Regarding complete loss of corneal sensation (score 2), in group II the median was 4 min while it was 5 min in group I, this result shows a statistically significant difference in time to onset of complete loss of corneal sensations across study groups. ($P = 0.036$)

With regard to globe and lid akinesia median was 3 min for partial akinesia (score 1) in group II, and 5 min in group I. This also show statistically significant difference in time to partial akinesia across study groups. ($P < 0.001$)

The same was found in complete akinesia (score 0) where median was 5 min in group II and 15 min in group I. a statistically significant difference was found in time to complete motor akinesia across study groups. ($P < 0.001$)

This study shows that there were no significant difference in the onset of partial loss of corneal sensation across study group.

This goes with the results of **Mogahed *et al*.** [39] in their randomized double-blind prospective study which was carried out on 96 ASA I and II patients aged 40 to 65 years who were scheduled for elective vitreoretinal surgery in Tanta university in 2017 found that adding Magnesium Sulfate as an adjuvant to Rocuronium Bromide, and local anaesthetic mixture in peribulbar anaesthesia for viteroretinal surgery had no statistically significant differences regarding the onset of corneal anesthesia between all groups.

In contrast the results of this present study goes with the results of **Abd Elhamid**[40] , his study was done in Benha university hospitals comprised 60 patients belonging to ASA physical status I and II, undergoing posterior segment eye surgeries aged 18 to 60 years. Using local anesthetic + Magnesium Sulfate 50 mg (in 1 ml 0.9% saline). He reported that administration of magnesium as an adjuvant to the local anesthetic in peribulbar anesthesia accelerated the onset of sensory and motor block without any side effects.

It also in agreement with the results of **Mogahed *et al.***[41] The study was conducted in Tanta University Hospital between June 2016 and November 2016. design was a prospective, double-blind, randomized, and controlled trial, on 105 patients undergoing routine cataract extraction surgery, patients were ASA I–III and received peribulbar anesthesia using a mixture of 0.5% Ropivacaine, 1 ml (150 IU) Hyaluronidase and 50 mg/100mg of Magnesium Sulfate.

They found that Addition of 50 mg or 100 mg of Magnesium Sulfate to Ropivacaine in peribulbar block led to rapid onset and prolonged duration of sensory and motor blockade without adverse effects with reduction of the postoperative analgesic requirements. The results were more significant on using 100 mg magnesium sulfate.

Mohamed *et al.*[42] in a prospective, randomized, double blinded study was carried out in the hospital of El-Minia university from November 2016 to March 2017. The study comprised 66 patients, ASA physical status I or II of both sexes scheduled for phacoemulsification of cataract and intraocular lens implantation under peribulbar anesthesia, their age ranged between 40 and 60 years. Patients received peribulbar anesthesia using a mixture of Lidocaine 2% with 120 IU of Hyaluronidase + Bupivacaine 0.5% + 50 mg Magnesium Sulfate 10 % in 1 ml of 0.9% saline.

They found that addition of 50 mg of Magnesium 10% to local anesthetic mixture for peribulbar anesthesia in the operations of phacoemulsification of cataract and intraocular lens implantation accelerated the onset of globe anesthesia, akinesia of the globe and the lid, prolong the duration of globe akinesia, lid akinesia, time to 1st analgesic request, and enhanced the satisfaction of the patients and quality of the operative conditions. Which goes with the results of the present study.

The results of this study goes also with the results of **Sinha *et al.***[43] in their study on 60 patients to examine the effect of adding 50 mg Magnesium Sulfate to a mixture of Lidocaine 2% and Bupivacaine 0.5% in peribulbar anesthesia for ophthalmic surgeries, and they found that adding Magnesium Sulfate to the anesthetic mixture accelerated onset of anesthesia and shortened the time for suitable conditions to start surgery without any side effects.

Contralateral to our study **Hamawy and Bestarous**[44] in their prospective double-blind randomized controlled study in2012 at Ain Shams University Hospitals which included 75 patients of either sex who were candidates for cataract surgery,between 40 and 80 years of age, with an ASA physical status of I–III, found that adding 50 mg Magnesium Sulfate to the local anesthetic mixture in peribulbar anesthesia had no beneficial effects on the onset of the block or akinesia score.

On the other hand to our results **Lee *et al.***[45] observed no difference in onset times and durations of sensory and motor blocks in Magnesium Sulfate group and normal saline group with 0.5% Bupivacaine with Epinephrine in interscalene nerve block for arthroscopic rotator cuff repair. They only found statistically significant prolongation of analgesia in the magnesium group than in the saline group.

In disagreement with the current study a meta-analysis done by **Morrison AP *et al.***found that the addition of intrathecal magnesium to local anesthetic did not result in a significant delay on the onset nor prolonged duration of sensory blockade. [46]

In agreement with our results **Shruthi A H *et al.***[47] in a prospective, double-blind, randomized control study was conducted in 40 patients, Found that Magnesium Sulfate as an adjuvant provides rapid onset of epidural anesthesia and prolongs the duration of analgesia with minimal side effects.

R. A. Hamed *et al.*[48] in a double-blind, randomized control study on ninety patients scheduled for

elective surgeries on the upper limb under ultrasound guided supraclavicular brachial approach found that Magnesium was proved to prolong the duration of block and the analgesia time and fasten the sensory block onset time, these findings goes with the results of the present study.

Also Narang ***et al***in a prospective, double-blind, randomized study conducted in 30 ASA physical status I or II patients undergoing upper limb surgery under tourniquet. Their findings indicate that Magnesium Sulfate added as an adjuvant to Lidocaine hasten the onset of sensory and motor block,[38] which supports the results of the present study.

Dogru *et al*.[49] The study was aimed to compare the effect of adding Magnesium to Levobupivacaine on sensory and motor block onset and duration for axillary brachial plexus block in chronic renal failure patients scheduled for arteriovenous fistule surgery. 80 patients, ASA III, aged 30 to 70 years, and received levobupivacaine and Magnesium Sulfate (150 mg) mixture by perineural axillary brachial plexus block.
They found statistically decreased motor and sensory block onset times by the addition of Magnesium to Levobupivacaine for axillary brachial plexus block in chronic renal failure patients scheduled for arteriovenous fistula surgery, which coincides with the results of the present study.

REFERENCES:

1. **Malik, A., Fletcher, E. C., Chong, V., & Dasan, J.** (2010). Local anesthesia for cataract surgery. *Journal of Cataract & Refractive Surgery*, *36*(1), 133-152.
2. **Boyd, B. F.** (1975). Personal interview between the editor and RC Troutman, D Paton, S Ryan. *Present trends in incision closure of the cataract wound*. *Highlights Ophthalmol*, *14*, 176-204.
3. **Fichman, R. A.** (1996). Use of topical anesthesia alone in cataract surgery. *Journal of Cataract & Refractive Surgery*,*22*(5), 612-614.
4. **Kallio, H., & Rosenberg, P. H.** (2005). Advances in ophthalmic regional anaesthesia. *Best Practice & Research Clinical Anaesthesiology*, *19*(2), 215-227.
5. **Linebarger, E. J., Hardten, D. R., Shah, G. K., & Lindstrom, R. L.** (1999). Phacoemulsification and modern cataract surgery. *Survey of ophthalmology*, *44*(2), 123-147.
6. **Seibel, B. S.** (2004). *Phacodynamics: mastering the tools and techniques of phacoemulsification surgery*. Slack Incorporated.
7. **Ernest, P. H.** (1994). Cataract incision architecture. *International ophthalmology clinics*, *34*(2), 31-57.
8. **Schein, O. D., Bass, E. B., Sharkey, P., Luthra, R., Tielsch, J. M., Javitt, J. C., & Steinberg, E. P.** (1995). Cataract surgical techniques: preferences and underlying beliefs. *Archives of Ophthalmology*, *113*(9), 1108-1112.
9. **Feibel, R. M.** (1985). Current concepts in retrobulbar anesthesia. *Survey of ophthalmology*, *30*(2), 102-110.
10. **Vargas, L. G., Peng, Q., Escobar-Gomez, M., Schmidbauer, J. M., & Apple, D. J.** (2001). Overview of modern foldable intraocular lenses and clinically relevant anatomy and histology of the crystalline lens. *International ophthalmology clinics*, *41*(3), 1-15.
11. **Alió, J., Rodriguez-Prats, J. L., & Galal, A.** (2006). Advances in micro-incision cataract surgery intraocular lenses. *Current opinion in ophthalmology*, *17*(1), 80-93.
12. **Crandall, A. S.** (2001). Anesthesia modalities for cataract surgery. *Current opinion in ophthalmology*, *12*(1), 9-11.
13. **Davis, D. B., & Mandel, M. R.** (1986). Posterior peribulbar anesthesia: an alternative to retrobulbar anesthesia. *Journal of Cataract & Refractive Surgery*, *12*(2), 182-184.
14. **Canavan, K. S., Dark, A., & Garrioch, M. A.** (2003). Sub-Tenon's administration of local anaesthetic: a review of the technique. *British journal of anaesthesia*, *90*(6), 787-793.
15. **Hansen, E. A., Mein, C. E., & Mazzoli, R.** (1990). Ocular anesthesia for cataract surgery: a direct sub-Tenon's approach. *Ophthalmic Surgery, Lasers and Imaging Retina*,*21*(10), 696-699.
16. **Rocha, G., & Turner, C.** (2007). Safety of cataract surgery under topical anesthesia with oral sedation without anesthetic monitoring. *Canadian Journal of Ophthalmology/Journal Canadien d'Ophtalmologie*, *42*(2), 288-294.
17. **Kershner, R. M.** (1993). Topical anesthesia for small incision self-sealing cataract surgery: a prospective evaluation of the first 100 patients. *Journal of Cataract & Refractive Surgery*,*19*(2), 290-292.
18. **Rubin, A. P.** (1995). Complications of local anaesthesia for ophthalmic surgery. *British journal of anaesthesia*, *75*(1), 93-96.
19. **Wong, D. H.** (1993). Regional anaesthesia for intraocular surgery. *Canadian Journal of Anaesthesia*,*40*(7), 635-657.
20. **Vettese, T., & Breslin, C. W.** (1985). Retrobulbar anesthesia for cataract surgery: comparison of Bupivacaine and Bupivacaine/Lidocaine combinations. *Canadian journal of ophthalmology. Journal canadien d'ophtalmologie*, *20*(4), 131-134.

21. **Zahl, K., Jordan, A., McGroarty, J., & Gotta, A. W.** (1990). pH-adjusted Bupivacaine and Hyaluronidase for peribulbar block. *Anesthesiology*, *72*(2), 230-232.
22. **Sarvela, J., Nikki, P., & Paloheimo, M.** (1993). Orbicular muscle akinesia in regional ophthalmic anaesthesia with pH-adjusted bupivacaine: effects of Hyaluronidase and Epinephrine. *Canadian journal of anaesthesia*, *40*(11), 1028.
23. **Bharti, N., Madan, R., Kaul, H. L., Khokhar, S. K., & Mishra, S.** (2002). Effect of addition of Clonidine to local anaesthetic mixture for peribulbar block. *Anaesthesia and intensive care*,*30*(4), 438.
24. **Weijtens, O., Schoemaker, R. C., Lentjes, E. G., Romijn, F. P., Cohen, A. F., & van Meurs, J. C.** (2000). Dexamethasone concentration in the subretinal fluid after a subconjunctival injection, a peribulbar injection, or an oral dose.*Ophthalmology*, *107* (10), 1932-1938.
25. **Roberts, J. E., MacLeod, B. A., & Hollands, R. H**. (1993). Improved peribulbar anaesthesia with alkalinization and Hyaluronidase. *Canadian journal of anaesthesia*, *40*(9), 835.
26. **Reah, G., Bodenham, A. R., Braithwaite, P., Esmond, J., & Menage, M. J.** (1998). Peribulbar anaesthesia using a mixture of local anaesthetic and Vecuronium. *Anaesthesia*, *53*(6), 551-554.
27. **Küçükyavuz, Z., & Arici, K. M.** (2002). Effects of Atracurium added to local anesthetics on akinesia in peribulbar block.*Regional anesthesia and pain medicine*, *27*(5), 487-490.
28. **Aissaoui, Y., Belyamani, L., & Kamili, N. D.** (2010). Effect of the addition of Rocuronium to local anesthetics for peribulbar block. *Acta Anaesthesiol Belg*, *61*, 51-4.
29. **Širvinskas, E., & Laurinaitis, R.** (2002). Use of Magnesium Sulfate in anesthesiology. *Medicina (Kaunas)*, *38*(7), 695-698.
30. **Malleeswaran, S., Panda, N., Mathew, P., & Bagga, R.** (2010). A randomised study of Magnesium Sulphate as an adjuvant to intrathecal Bupivacaine in patients with mild preeclampsia undergoing caesarean section. *International journal of obstetric anesthesia*, *19*(2), 161-166.
31. **Yousef, A. A., & Amr, Y. M.** (2010). The effect of adding Magnesium Sulphate to epidural Bupivacaine and Fentanyl in elective caesarean section using combined spinal–epidural anaesthesia: a prospective double blind randomised study. *International journal of obstetric anesthesia*, *19*(4), 401-404.
32. **Ghatak, T., Chandra, G., Malik, A., Singh, D., & Bhatia, V. K.**(2010). Evaluation of the effect of Magnesium Sulphate vs. Clonidine as adjunct to epidural Bupivacaine. *Indian journal of anaesthesia*, *54*(4), 308.
33. **Farouk, S.** (2008). Pre-incisional epidural magnesium provides pre-emptive and preventive analgesia in patients undergoing abdominal hysterectomy. *British journal of anaesthesia*,*101*(5), 694-699.
34. **Gunduz, A., Bilir, A., & Gulec, S.** (2006). Magnesium added to Prilocaine prolongs the duration of axillary plexus block. *Regional anesthesia and pain medicine*, *31*(3), 233-236.
35. **35-Hung, Y. C., Chen, C. Y., Lirk, P., Wang, C. F., Cheng, J. K., Chen, C. C., ... & Gerner, P**. (2007). Magnesium sulfate diminishes the effects of amide local anesthetics in rat sciatic-nerve block. *Regional anesthesia and pain medicine*, *32*(4), 288-295.
36. **Hwang, J. Y., Na, H. S., Jeon, Y. T., Ro, Y. J., Kim, C. S., & Do, S. H.** (2009). IV infusion of Magnesium Sulphate during spinal anaesthesia improves postoperative analgesia. *British journal of anaesthesia*, *104*(1), 89-93.
37. **Elsharnouby, N. M., & Elsharnouby, M. M.** (2006). Magnesium Sulphate as a technique of hypotensive anaesthesia. *BJA: British Journal of Anaesthesia*, *96*(6), 727-731.
38. **Narang, S., Dali, J. S., Agarwal, M., & Garg, R.** (2008). Evaluation of the efficacy of Magnesium Sulphate as an adjuvant to lignocaine for intravenous regional anaesthesia for upper limb surgery. *Anaesthesia and intensive care*, *36*(6), 840.
39. **Mogahed MM, Nassar WM, Abdullah MA**. (2017) Dexmedetomidine *vs.* Magnesium Sulphate as an Adjuvant to Rocuronium Bromide, and Local Anaesthetic Mixture in Peribulbar Anaesthesia for Viteroretinal Surgery. *J Anesth Clin Res*,8, 745.
40. **El-Hamid, A. A.** (2011). Evaluation of the effect of Magnesium Sulphate vs Clonidine as adjunct to local anesthetic during peribulbar block. *Ain Shams J Anesthesiol*, *4*, 21-26.
41. **Mogahed, M., Anwar, A., & Abo elazm, W.** (2017). The Effect of Adding Two Different Doses of Magnesium Sulphate as Adjuvant to Ropivacaine in Peribulbar Block for Cataract Surgery. *J Anesth Clin Res.*, *08*(725).
42. **Mohamed, A. Z. E., & Genidy, M. M.** (2017). Magnesium Sulphate versus Dexmedetomidine as an adjuvant to local anesthetic mixture in peribulbar anesthesia. *Egyptian Journal of Anaesthesia*, *33*(4), 375-380.
43. **Sinha, R., Sharma, A., Ray, B. R., Chandiran, R., Chandralekha, C., & Sinha, R.** (2016).

Effect of addition of Magnesium to local anesthetics for peribulbar block: A prospective randomized double-blind study. *Saudi journal of anaesthesia*, *10*(1), 64.

44. **Hamawy, T., & Bestarous, J.** (2013). Rocuronium versus Magnesium as an adjuvant to local anesthetics in peribulbar block. *Ain-Shams Journal of Anaesthesiology*, *6*(3), 317-317.
45. **Lee, A. R., Yi, H. W., Chung, I. S., Ko, J. S., Ahn, H. J., Gwak, M. S., ... & Choi, S. J.** (2012). Magnesium added to Bupivacaine prolongs the duration of analgesia after interscalene nerve block. *Canadian Journal of Anesthesia/Journal canadien d'anesthésie*, *59*(1), 21-27.
48. *Middle East journal of anaesthesiology*, *23*(4), 449-455.
49. **Hamed, R. A., Osman, N. M., Hassan, W. S., & Omar, S. M.** (2016). Abstract PR295: Dexamethasone Versus Magnesium Sulfate As An Additives to Bupivacaine in Ultrasound Guided Supraclavicular Brachial Plexus Blockade. *Anesthesia & Analgesia*, *123*(3S_Suppl), 376.
46. **Morrison, A. P., Hunter, J. M., Halpern, S. H., & Banerjee, A.** (2013). Effect of intrathecal magnesium in the presence or absence of local anaesthetic with and without lipophilic opioids: a systematic review and meta-analysis. *British journal of anaesthesia*, *110*(5), 702-712.
47. **Shruthi, A. H., Sudheesh, K., Nethra, S. S., Raghavendra, R. R., & Devika, D. R**. (2016). The effect of a single dose of Magnesium Sulphate as an adjuvant to epidural bupivacaine for infraumbilical surgeries: a prospective double-blind, randomized control trial.
50. **Dogru, K., Yildirim, D., Ulgey, A., Aksu, R., Bicer, C., & Boyaci, A.** (2012). Adding Magnesium to Levobupivacaine for axillary brachial plexus block in arteriovenous fistule surgery. *Bratislavske lekarske listy*, *113*(10), 607-609.