CODEN [USA]: IAJPBB ISSN : 2349-7750

INDO AMERICAN JOURNAL OF
PHARMACEUTICAL SCIENCES
SJIF Impact Factor: 7.187
https://doi.org/10.5281/zenodo.5227190

Online at: http://www.iajps.com *Review Article*

COMPREHENSIVE REVIEW OF INFECTED NON-UNION TIBIAL

Mohammed Hassan Al Harthi, Faisal Omar Alrefaei, Bushra Mukhtar Alshanqiti, Mohammed Saad Alghamdi

Article Received: July 2021 **Accepted:** July 2021 **Published:** August 2021

Abstract:
In this review we overviewed the diagnostic and management approaches of infected nonunion tibi and preference over others. We performed an overview of the literature with the use of the medical databases such; Medline and EMBASE. All researches related to the inflamed nonunion of the tibia have been focused in our search. We covered research published up to January, 2021. inflamed nonunion of tibia and femur prevail in clinical technique. some coexisting issues generally make the nonunion infected tibia complicated in which contamination of bone and soft tissue loss, limb-period inequalities, disorder, and joint stiffness. that make it absolutely a trouble for orthopedic surgeons about choosing the management of infected nonunion of tibia and femur. several diverse surgical remedy alternatives had been recommended, such as bone grafting, loose tissue switch, antibiotic therapy, and Ilizarov strategies. There are some constraints in bone grafting, together with the scale of bone defects, donor site morbidity, and prolonged graft consolidation time. Although free tissue transfer appropriates for the therapy of large bone and soft tissue loss, it is a technically requiring surgical intervention, and it is typically associated with stress fractures and nonunion tibia.

Corresponding author:
Mohammed Hassan Al Harthi,

QR code

Please cite this article in press Mohammed Hassan Al Harthi ***et al.****,* ***Comprehensive Review Of Infected Non-Union Tibial****.., Indo Am. J. P. Sci, 2021; 08(08).*

INTRODUCTION:

Tibial shaft non-union is into consideration the most typical form of long bone non-union, the etiological factors are due to high prevalence of intense open fractures, high strength trauma related to vascular and smooth tissue destruction, infection and bone devitalization and segmental bone loss. Fractures of long bones aren't most effective complex surgical intervention problems but additionally chronic and may be devastating issues. Nonunion of long bones is not truly a useful resource of functional weak point yet in addition can result in economic hassle and also lack of self-confidence. The issue appears to be expanding, specially due to the fact raising high-pace damage, that's extra normally dealt with inner fixation [1], [2].

Persistent infection of the diaphysis shaft of long bones such tibia is simply certainly one of the most urging problems in orthopedic surgical field. Infection of the ununion long bones normally need a further radical debridement of the septic bone and soft tissue together with the application of constant dependency to improve gentle tissue regeneration in addition to bony union. Papineau-type open cancellous bone grafting, tibiofibular synostosis, cancellous allograft in fibrin sealant combined with anti-biotics, and/or free microvascular soft tissue and bone transplants [3].

Infected nonunion of the tibia posture significant difficulties for total resolution and practical restoration. The infection is chronic and resistant to treatment. In this review we discuss the diagnosis and management approaches of infected nonunion of tibia as well advantages of some techniques over others.

METHODOLOGY:

We conducted a narrative review of the literature using the online databases such; MEDLINE, Life Science Citations, PubMed, Google Scholar and EMBASE Biochemical. Studies involving the Infected nonunion of the tibia were targeted in our search. We included studies published up to January, 2020. restriction to English language and human subject databases accessed to search studies with no limits set during research, Terms aimed at capturing the target diagnosis, such as “infected tibial nonunion” and “fixation” were combined using the MeSH terms.

DISCUSSION:

Infected non-union of the tibia continues to be difficult issue in medical and surgical orthopaedic field, mainly with presence of bone and soft-tissue involvement, it became proved that ilizarov outside fixator display a excessive price of achievement in the treatment of such tough cases [2]. Debridement of devitalized bone and soft tissue, antibiotic begin can lead to improvement with less complicated infections, while in sever form of bone infections need radical debridement, strong external fixator and bone grafting or compression distraction are obligatory to advantage bone union [1],[2]. Papineau approach, tibiofibular synostosis, other bone substitutes is of restricted capability to reconstruct the limb duration discrepancy and to correct the limb deformity [2].

- **Diagnosis and classifications:**

Infected nonunion are very easy to diagnose but complicated to to treat. Limited mobility afterward is common in many case of nonunion infected tibia. Many further defect as malunions with little mobility, mainly with a united fibula. long leg films monitor degree of bony involvement, limb positioning, and additionally length discrepancy. X-rays divulge sequestrate, osteoporosis, defects, and additionally compromise of the bony space. Indirect x-rays can divulge the gap as well as verify the scientific analysis of a nonunion tibia [4]. Improved acute section stimulant tiers affirm energetic infection as well as ease of diagnosis. Serological marker screening for hepatitis B surface area antigen, HIV, in addition to hepatitis C is essential. High probabilities of more other type of infections, and additionally the discharge secretions on infected area can cause hospital acquire infections of other patients in the ward [5]. Infected nonunions of tibia can show several problems to the handling medical professional and the affected person. Problems include recalcitrant contamination, complicated deformities, sclerotic bone ends, big bone gaps, shortening, and joint tightness. The ASAMI category assists decide therapy. Classification of infected nonunion should have prognostic worth and aid choose treatment. ASAMI classification is generally utilized (Table 1) [6]. Infection is classified as active or dormant.

Table 1. ASAMI classification of nonunion [6].

○ A-Aseptic nonunion without bone defect
A1 Mobile (atrophic/hypotrophic)
A2 Stiff without deformity (hypertrophic)
A3 Stiff with deformity (hypertrophic)
○ B-Aseptic nonunion with bone defect
B1 Length of limb preserved with bone defect
B2 Segment in contact with shortening of limb
B3 Combined shortening with defect
○ C-Infected nonunion

Severity of infection:
Complications Pinsite infection, knee stiffness, K-wires loosening, recurrence of wound infection, regenerate fracture, Malunion, paranesthesia, soft tissue impingement and Mortality was reported. Pin tract, infection was the most common complication and it was managed by antibiotics in most of the reviewed studies. The infection severity score (ISS) qualities severity of infection by evaluating 6 medical criteria [7]. The score is easy to compute. Maximum score is 25, which is transformed to 100. Higher ratings point to need for a second debridement and possibility of insufficient removal or reappearance of infection. It might suggest using exterior instead of internal addiction in the 2nd phase as a conclusive method to attain union.

Lower scores point to alleviate of elimination of the infection. Lower scores can permit definitive inner fixation in the 2nd stage or outside fixation in the very same phase. ISS would help grade residual infection if any.

- **Management methods:**

Management using llizarov technique:
This technique is regarded by numerous surgeons as a General management in infected nonunion. It's suitable but could be wasting time operation, suitable for extraordinarily in some and inspired patients [8]. The technique can attend to plenty of issues concurrently: bone deformities, deformity, malrotation, limb-period discrepancy, and nonunion [9]. It is the maximum official method for regaining a health and normal bone. There more than sixty patients reported managed with this method and mentioned in the literature in the past decade. There are different methods of the use of the llizarov in infected nonunion; if there may be no bone problem, the nonunion may be compressed and the placing stored up until union. infected is not irradiated or treated. If there's bone deformity to begin with or after bone debridement, there are 2 options: acute shortening or bone shaft. Acute shortening is observed through limb extending to recover length [10]. Acute shortening causes arteriolar occlusion and formation of scar tissue, which would possibly cause hassle with later limb duration healing. Bone transplant is a great strategy for closure of big bone gaps. The benefit of this procedure is that there is simultaneous soft tissue transplantation, but the negative aspect is that the delivered soft tissue is atrophic and makes a poor soft tissue envelope [10]. This kind of soft tissue protection is not suitable for infected non-union as the soft tissue coverage over the docking site might be slim and oversensitive [13]. Soft tissue closure can also be followed by skin traction throughout bone graft. The llizarov method can be successfully applied in young patient with great satisfying outcome [12]. In conclusion, bone grafting outcomes are great to exceptional in 80% and functional results are good to excellent in 66.7%. The practical outcomes are, as a basic guideline, poorer contrasted to bone results [11]. Practical results rely on the extent of destruction occurred to soft tissue at the time of injury and or throughout succeeding medical interventions. The issue rate associated with using llizarov method might reach 87%. It should be borne in mind that these patients are neglected situations with numerous unsuccessful previous procedures, and it is challenging to choose whether these patients' limbs must be amputated or salvaged.

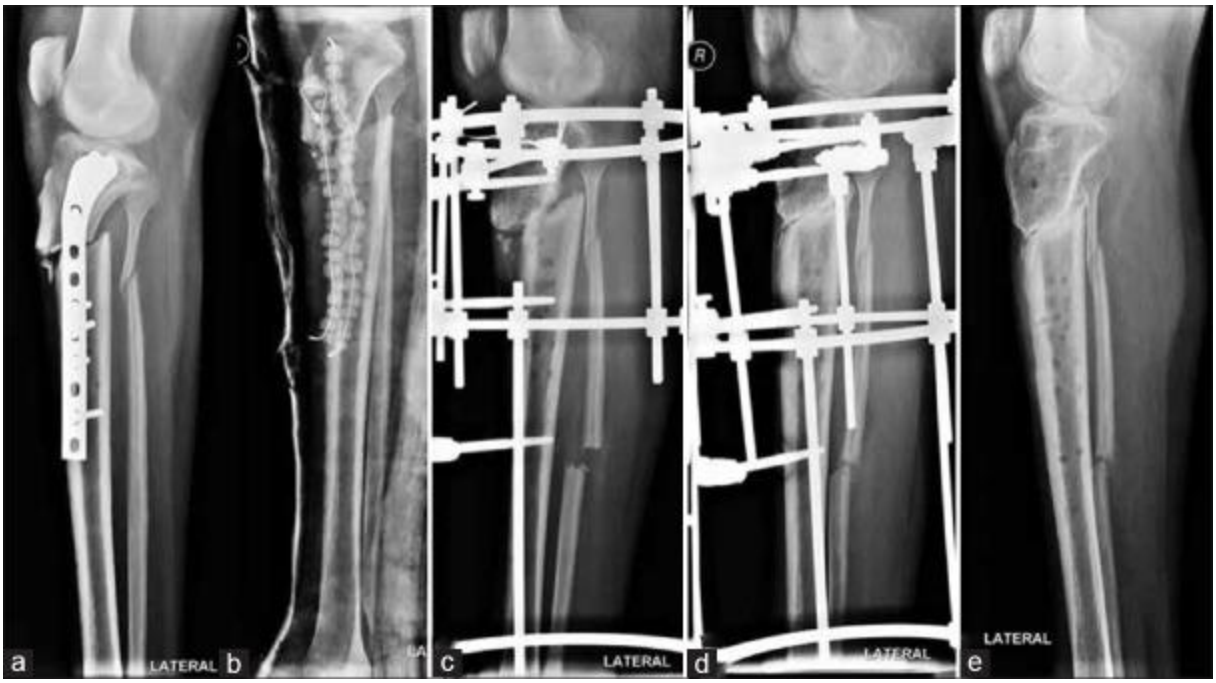

Figure 1. Oblique view of leg bones with knee showing (a) upper tibial infected nonunion (b) After infection control (c) Ilizarov apparatus in situ (d). If vertical compression is given, it causes vertical displacement of nonunion ends. With the help of washers, horizontal compression achieved perpendicular to plane of nonunion (e) Good union. No loss of length [14].

Intramedullary devices with or without external fixators

Bone transport over an intramedullary device is a relatively new technique in the treatment of afflicted nonunion. The advantages of this method are; fracture stabilizing, prevention of limb reducing and malrotation, and early partial weight-bearing [15]. There are 43 reported patients that have been treated with this type of personnel method [16]. This technique still requires to be evaluated. Inner fixation (plating) has not been reported in the management of infected nonunion of long bones [18].

Grafting of soft tissue:

Free tissue transfer (bone, soft tissue or both) are technically requiring, and require close co-operation in between plastic and orthopedic surgeons. Choices for vascularized bone are; fibula, iliac crest, ribs, and scapula. Cheng et al. made use of vascularized two ribs graft plus serratus anterior in six patients with infected nonunion [19]. All cracks joined, and infection was regulated, however there were two stress cracks of the dental implanted ribs. The fractures were dealt with non-operationally and they united. Vascularized bone and tissue can be made use of in difficult infections. Yasunori et al. utilized fibular grafts in contaminated nonunion triggered by Methicillin-Resistant Staphylococcus Aureus (MRSA), obtaining union in 18/20 90% [17], [20]. Infection was regulated using the two-phase technique. The two-stage approach gives an organic setting which is essential for healing of bone and soft tissue.

Not all infected nonunions require challenging procedures. In situ reconstruction does provide an option. Small problems (2-4 cm) can be properly treated with easier techniques, utilizing the exact same two-stage strategy. Cancellous bone-grafting (with or without antibiotics) is done in the 2nd stage [21]. Soft tissue coverage can be obtained by either neighborhood or vascularized muscle flap (Figure 2). Prescription antibiotics mixed with cancellous bone during the second phase provides high regional concentration of the anti-biotics for as much as 3 weeks without systemic indications of antibiotic poisoning. The effect(s) of blending antibiotics with cancellous bone grafting (regarding bone union or incorporation) is not known at this stage. The method is very efficient in the eradication of infection: up to 94.4% success rate [21]. In situ fibular transfer has been efficiently utilized in youngsters with tibial infected nonunion. Haluk et al. used this method in four kids [22]. He obtained union in all and infection was efficiently removed. The angular defect that takes place so generally after this treatment will certainly

deal with spontaneously in most youngsters. Vascularised fibular transfer can also be executed in children, without impacting growth of the donor leg [23].

Eliminating fibrous tissue, necrotic bone, and opening the marrow canal improve blood supply and enable nutrients and antibiotics to get to the site. An antibiotic impregnated cement block obliterates dead area. It allows elution of the antibiotic in very high focus at the local site, in numerous multiples of the minimum inhibitory concentration (MIC) [24]. Acrylic bone cement is made into intramedullary (IM) rods (with a core of a K cord or Rush nail/V nail). The rod is inserted from proximal portal after reaming. In flawed canals, one cement rod is inserted in the proximal canal and an additional in the distal through the nonunion site. Cement beads are strung on an SS wire in the extramedullary part. Adding the antibiotic powder or fluid towards the end of polymerization makes certain higher elution of antibiotics [25].

The cement can be made right into a block to inhabit the entire bony gap. Conversely, the concrete may be made as a cyndrical tube and Rush or Ender nails travelled through it to protect the cement block to the bone.

Just recently, a huge diameter nail with a double core of antibiotic cement around a steel rod has been used for substance fractures with great impact [26]. This could be made use of for therapy of afflicted nonunion without significant bony gaps too.

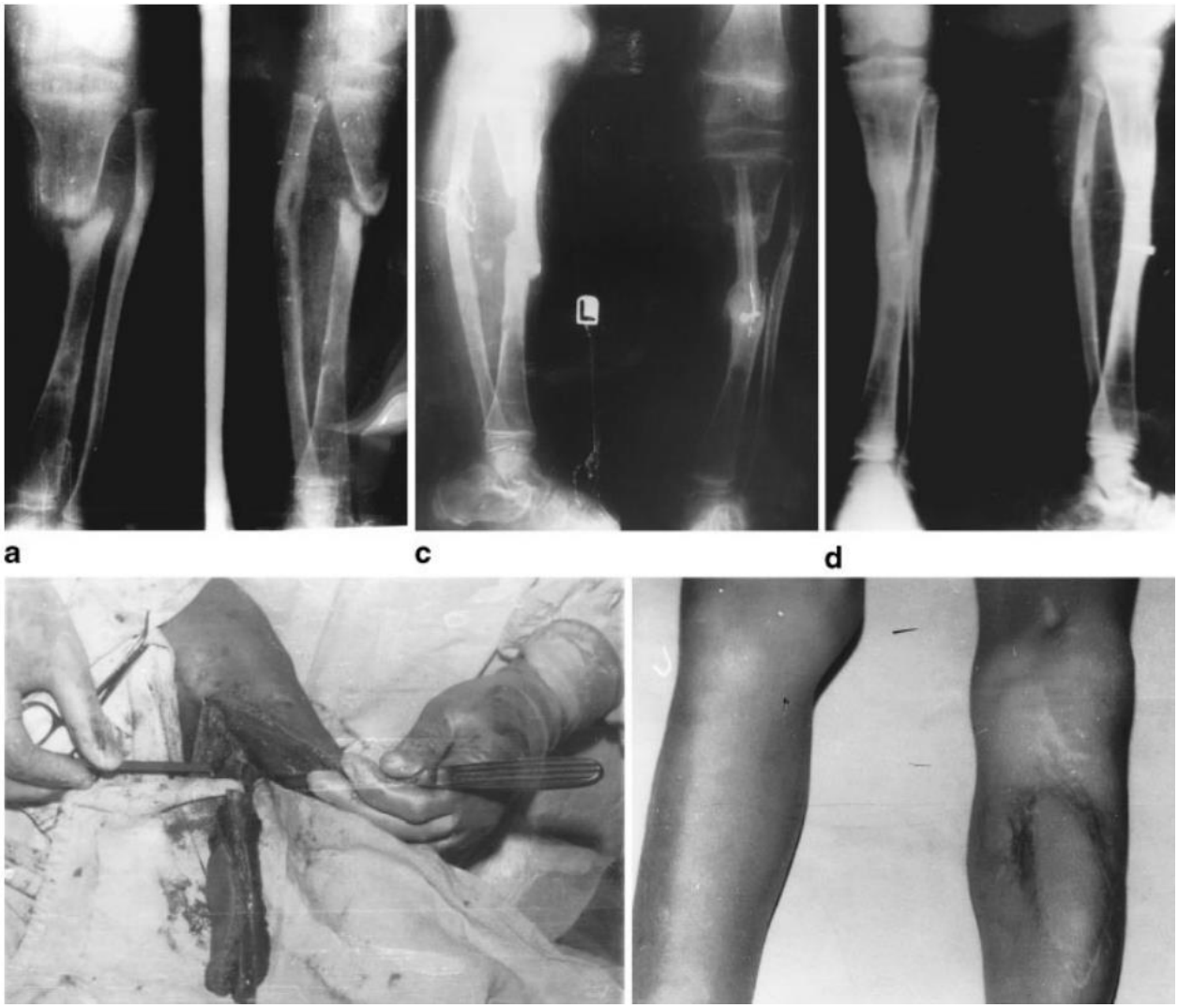

Figure 2: the preoperative radiograph of nonunion tibia fractured, and after debridement with defect smaller than 6cm. C showed radiograph 11 months post-operative, the E skin island after 2 years.

In smaller spaces, an absorbable service provider might make the 2nd surgical procedure unnecessary. The use of calcium sulfate cement paste or powder and absorbable chitosan polymer service providers are great alternatives [27]. In moderate infection, debridement and definitive surgical treatments may be executed together. With ISS rating less than 25- 30, after detailed debridement and regional antibiotic delivery systems, one may take a chance with repeat interior fixation. Steady fixation with ABC rods itself can cause union in regarding 10- 15% of situations.

Utilizing interior fixation boosts threat of recurring infection in patients with greater ISS scores. Combined surgery of debridement and exterior addiction might be safe when the ISS score is less than or equal to 40. Greater ISS scores call for organized surgical procedure.

CONCLUSION:

Infected nonunion of tibia and femur prevail in clinical method. Some coexisting issues generally make complex the nonunion consisting of consistent infection, bone and soft tissue loss, limb-length inequalities, defect, and joint stiffness. Heretofore, there has actually still been a difficulty for orthopedic surgeons about the therapy of contaminated nonunion of tibia and femur. Several various surgical therapy options have been recommended, consisting of bone grafting, free tissue transfer, antibiotic cement, and Ilizarov techniques. There are some constraints in bone grafting, such as the size of bone defects, donor site morbidity, and prolonged graft consolidation time. Although free tissue transfer appropriates for the therapy of large bone and soft tissue loss, it is a technically requiring surgical procedure, and it is typically associated with stress fractures and nonunion. Antibiotic cement is utilized to manage the infection effectively, but it is just appropriate for the treatment of contaminated nonunion with small issues or none, and bone grafting is usually required to attain bone union. Ilizarov approaches can conquer all these difficulties and address coexisting problems all at once. Ilizarov apparatus is a very good choice for treating infected nonunion with a huge bone gap. Modern bone histogenesis complying with corticotomy and bone transportation help in loading bone spaces eliminating infection and advertising fracture union. Therefore, bone transportation has actually progressively been a major treatment for infected nonunion.

REFERENCE:

1. Vignes GS, Arumugam S, Ramabadran P. Functional outcome of infected non-union tibia fracture treated by Ilizarov fixation. Int J Sci Study 2014;2:87-92. Back to cited text no.
2. Bansal A, Bansal S, Singh R, Walia JP, Brar BS. Role of Ilizarov ring fixator in infected non union tibia. Int J Med Dent Sci 2014;3:451-9. Back to cited text no. 2
3. Yu P, Zhang Q, Mao Z, Li T, Zhang L, Tang P. The treatment of infected tibial nonunion by bone transport using the Ilizarov external fixator and a systematic review of infected tibial nonunion treated by Ilizarov methods. Acta Orthop Belg 2014;80:426-35.
4. Wijesekera MP, Graham SM, Lalloo DG, Simpson H, Harrison WJ. Fracture management in HIV positive individuals: A systematic review. Int Orthop. 2016;40:2429–45.
5. Javidan P, Walker RH. Take care with type C: Serious considerations in the selection of patients with hepatitis C for total joint arthroplasty. J Bone Joint Surg Am. 2015;97:e77.
6. Calori GM, Phillips M, Jeetle S, Tagliabue L, Giannoudis PV. Classification of nonunion: Need for a new scoring system? Injury. 2008;39(Suppl 2):S59–63.
7. Chaudhary Milind M. Infected gap nonunions of femur. In: Kulkarni GS, Babhulkar S, editors. Guidelines in Fracture Management, Nonunion in Long Bone II. Ch. 25. Noida: Thieme Publisher; 2016. pp. 309–24.
8. Arnez ZM, Smrke D. Treatment of extensive bone and soft tissue defects of the lower limb by traction and free-flap transfer. Injury Int J Care Injured 2000;31:153—62.
9. Chadha M, Maini L, Vishwanath J. The Ilizarov method in infected nonunion of fractures. Injury Int J Care Injured 2000;31:509—17.
10. Eshima I, Feibel RJ, Louie KW, Lowenberg DW. Combined muscle flap and Ilizarov reconstruction for bone and soft tissue defects. Clin Orthop Relat Res 1996;(November (332)):37—51.
11. Atesalp AS, Basbozkurt M, Komurcu M, Kurklu M. The treatment of infected tibial nonunion with aggressive Debride'- ment and internal bone transport. Mil Med 2002;167(12): 978—81.
12. Kabukcuoglu Y, kucukkaya M, Kuzugun U, Tezer M. Management of childhood chronic osteomyelitis with the Ilizarov method. J Paediatr Orthopaed 2002;22:632—7.
13. Kocialkowski A, Marsh DR, Shackley DC. Closure of the skin defect overlying infected nonunion by skin traction. Br J Plastic Surg 1998;51:307—10.
14. Chaudhary MM. Infected nonunion of tibia. *Indian J Orthop*. 2017;51(3):256–268.

15. Bu¨hren V, Gonschorek O, Hofmann GO. Segmental transport employing intramedullary devices in tibial bone defects following trauma and infection. J Orthop Trauma 1999; 13(3):170—7.
16. Eralp L, Kocaoglu M, Rashid H, et al. Reconstuction of segmental bone defects due to chronic osteomyelitis with use of an external fixator and an intramedullary nail. J Bone Joint Surg 2006;88-A(October (10)):2137—45.
17. Eshima I, Feibel RJ, Louie KW, Lowenberg DW. Combined muscle flap and Ilizarov reconstruction for bone and soft tissue defects. Clin Orthop Relat Res 1996;(November (332)):37—51.
18. Hahn D, Olson S. Surgical treatment of nonunions: a case for internal fixation.. Injury Int J Care Injured 2006;37: 681—90.
19. Cheng S-L, Chuang David DC-C, Shih C-H, Ueng SW-N. Management of large infected tibial defects with radical Debride'- ment and staged double-rib composite free transfer. J Trauma Injury Infect Crit Care 1996;40(3):345—50.
20. Kobata Y, Shigematsu K, Yajima H. Vascularized fibular grafting in the treatment of methicillin-resistant Staphylococcus Aureus osteomyelitis and infected nonunion. J Reconstr Microsurg 2004;20:1—12.
21. Chan Y-S, Ueng SW-N, Wang C-J, et al. Management of small infected tibial defects with antibiotic-impregnated autogenic cancellous bone grafting. J Trauma Injury Infect Crit Care 1998;45(October (4)):758—64.
22. Agus H, Arslantas M, Kalenderer O, Ozcalabi IT. Treatment of infected pseudoarthrosis of the tibia by in situ fibular transfer in children.. Injury Int J Care Injured 2005;36:1476—9.
23. Haopeng L, Liaosha J, Xijing H. Functional development of the donor leg after vascularized fibula graft in childhood. J Paediatr Surg 2000;35(August (8)):1226—9.
24. Gogia JS, Meehan JP, Di Cesare PE, Jamali AA. Local antibiotic therapy in osteomyelitis. Semin Plast Surg. 2009;23:100–7.
25. Chang YH, Tai CL, Hsu HY, Hsieh PH, Lee MS, Ueng SW. Liquid antibiotics in bone cement: An effective way to improve the efficiency of antibiotic release in antibiotic loaded bone cement. Bone Joint Res. 2014;3:246–51.
26. Craveiro-Lopes N. Treatment of open fractures of the tibia with locked intramedullary nail with a core release of antibiotics (Safe Dualcore Universal). Comparative study with a standard locked intramedullary nail. J Limb Lengthening Reconstr. 2016;2:17–22.
27. Ślósarczyk A, Czechowska J, Paszkiewicz Z, Zima A. New bone implant material with calcium sulfate and Ti modified hydroxyapatite. J Achiev Mater Manuf Eng. 2010;43:170–7.