CODEN [USA]: IAJPBB ISSN : 2349-7750

INDO AMERICAN JOURNAL OF
PHARMACEUTICAL SCIENCES
SJIF Impact Factor: 7.187
https://doi.org/10.5281/zenodo.6258372

Available online at: http://www.iajps.com *Research Article*

ZYGOMA GEAR APPLIANCE APPROACH FOR MOLAR DISTALIZATION

[1]Shaza Jameel Ashqar, [2]Omar Seraj Omar Shafei, [3]Shareefah Mousa Asiri, [4]Rania Ibrahim AlMowalad, [5]Najat Bakr Suliman Ibrahim, [6]Salha Bakur Suliman Ibraheem

Article Received: September 2021 **Accepted:** September 2021 **Published:** October 2021

ABSTRACT:
The review aimed to overview the Zygma gear appliance for molar distalization and its benefits over other methods. We conducted this narrative review through searching the electronic databases such PubMed, Embase for all relevant studies that were published in English language up to the end of 2020. In conclusion, the evidence based showed that for this instance the ZGA was an efficient system to distalize upper molars without anchorage loss. Absolute anchorage control was provided by using zygomatic anchorage plates during the distalization of molars as well as the retraction of incisors. The major negative aspect of this system was the minor surgeries to position as well as eliminate home plates. eveidance recommend that this new system can be made use of in nonextraction Class II treatment instead of extraoral and also intraoral distalization appliances.

Corresponding author:
Shaza Jameel Ashqar

QR code

Please cite this article in press Shaza Jameel Ashqar et al, ***Zygoma Gear Appliance Approach For Molar Distalization.,*** *Indo Am. J. P. Sci, 2021; 08(10).*

INTRODUCTION:

The traditional treatment of a independent Class II molar relationship with crookedness in the maxillary arc is the use of asymmetric extraoral traction in clients to be treated without tooth removals [1,2]. Although this method gives effective results in complying people, the lack of cooperation results in anchorage loss and also unsuitable treatment results. Furthermore, it has actually been shown that such a force [3].

The most standard technique for distalizing the maxillary molars entails use of cervical headwear, which can either be utilized for orthodontic or orthopedic improvements. It is simple to apply as well as may distalize not just the maxillary first molars yet likewise the first and also 2nd premolars using transeptal fibers [4]. Although it has been shown that an unilateral Class II malocclusion can be dealt with by headgear with the application of crooked facebows, the undesirable side pressures that tend to move maxillary molars right into crossbite were inescapable [5,6]. Furthermore, the success of the treatment depends heavily on individual cooperation, and also lack of person participation leads to anchorage loss as well as unsuitable therapy outcomes. The disadvantages of the extraoral home appliances have actually motivated numerous private investigators to establish the technicians of intraoral molar distalization [6].

To conquer the anchorage loss problems, clinicians described making use of intraosseous screws, onplants, as well as osseointegrated implants and plates [4,7]. However, the distalization period is delayed owing to the waiting period of 3 to 6 months for the palatal implants to achieve osseointegration. In addition, the bulky acrylic Nance appliance used behind the maxillary incisors might be a problem during retraction of the anterior teeth [8,9].

Recently, a new approach called the zygoma-gear appliance (ZGA) was described for the distalization of the maxillary molars. It was found to be effective for bilateral molar distalization [6]. However, only a few case reports have evaluated its efficiency for unilateral maxillary molar distalization [7,9].

This narrative review aimed to discuss the Zygoma gear approach in destination, and its benefits over the other methods.

DISCUSSION:

Several methods have been used for upper molar distalization consisting of extraoral as well as intraoral devices. The esthetic and social issues of using headgear wear as well as the anchorage loss that accompanies the application of intraoral systems have promoted numerous private investigators to use skeletal anchorage [2,8,9].

Several reports [10,11,12] have actually shown different appliances for molar distalization in the treatment of oral Course II malocclusions. However, anchorage loss of the maxillary premolars and also flaring of the maxillary incisors in addition to a considerable quantity of regression during retraction of the premolar and the former teeth were reported [13]. Therefore, intraoral distalizing technicians incorporated with palatal implants have actually lately been utilized for distalization of maxillary molars [12,13]. Although these techniques can be utilized properly to accomplish distalization of maxillary molars without anchorage loss, the retraction of the former teeth is restricted as a result of the closeness of palatal dental implant to the roots of former teeth or the presence of a bulky acrylic Nance home appliance behind the top incisors [13]. On top of that, Liou et al. [14] and also Kinzinger et al. [15] checked out the anchorage top quality of the miniscrews as well as wrapped up that they did not totally keep their placements under continuous loading. Sugawara et al. [16] reported that the zygomatic procedure of the maxilla can be utilized to avoid the anchorage loss. The ZGA has actually been produced as a noncompliance appliance, and also it has actually been revealed that it is possible to move maxillary molars distally with ease (**Figure 1**).

According to the outcomes of one study [18], the maxillary molars were properly distalized (4.37 mm) into overcorrected Class I molar relationship in 5.21 months, as well as, therefore, the average month-to-month distalization amount was found to be 0.84 mm. This quantity of tooth movement each month is similar to that produced by intraoral technicians sustained with a skeletal anchorage, varying from 0.66 to 1.2 mm each month. Gelgor et al. [17] located a distalization of 0.85 mm monthly by using intraosseous screw-supported anchorage; Escobar et al. 33 discovered 0.77 mm each month with the bone-supported pendulum; as well as Oberti et al. [18] discovered 1.18 mm monthly with a bone-supported molar distalizing device.

Karlsson and also Bondemark [19] showed that it is extra reliable to distalize the maxillary first molars

before the second molars have erupted. In addition, it is recommended to extract the third molars before distalization. In the same study, all second molars were erupted and none of the third molars were extracted before the distalization. Furthermore, an effective distalization was achieved in all patients treated with ZGA.

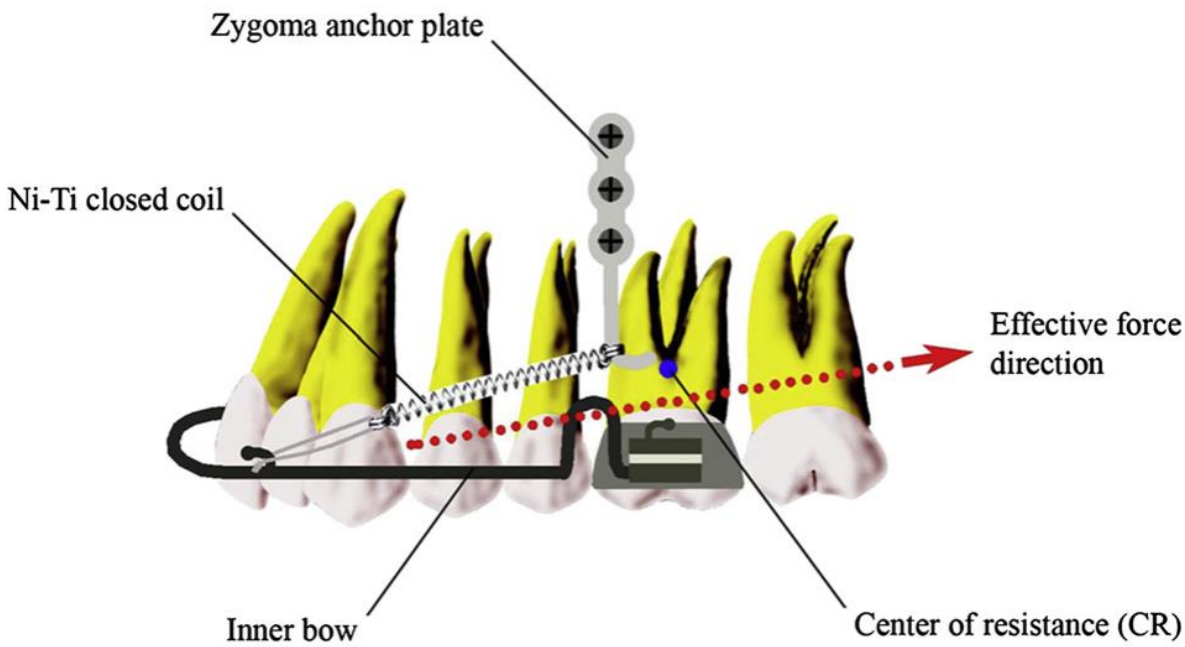

Figure 1: Schematic illustration of the components of the zygoma-gear appliance

Suguwara et al. [16] and Kaya et al. [8] utilized zygomatic anchorage for molar distalization and found around 3.50 mm in 19 months and also 4.5 - 5 mm in 9 months, specifically. In both research studies, buccal segmental distalization was executed, and various skeletal malocclusions (Class I, II, III and open bite) (with an average individual age of 23.1 years) were consisted of in the research study of Suguwara et al. [16] These might be feasible elements for the different findings. Yamada et al. [20] used miniscrew anchorage in the buccal interradicular area for distalization. Although the authors mentioned that effective molar distalization of 2.8 mm without person conformity and with no undesirable adverse effects was achieved, this amount is less than the ZGA quantity. Additionally, it is difficult to make use of the mechanism of Yamada et al. [20] for patients needing greater than 3 mm of molar distalization.

It is recommended that adhering to the distalization, the molars not be made use of for distalization and retraction of the various other teeth. With the ZGA, the molars are never required for anchorage during the retraction of the premolars and former teeth because the orthodontic forces can be given straight from the zygomatic support plates. On top of that, the maxillary main incisors were retruded after distalization, revealing that there was no anchorage loss by using the ZGA. As a matter of fact, first and 2nd premolars moved distally via transeptal fibers, as seen in the person displayed in (Figure 2).

The ZGA system offers anchorage from the zygomatic strengthen that is advised as a site for miniplate positioning because of its thick cortical plate.33-35 According to the searchings for of Nur et al, [6] 2 of 17 clients (11.8%) were omitted from the study due to infection, whereas Kaya et alia [8] reported that all miniplates used in their researches were stable throughout distalization, as well as no people were omitted from the study due to infection or mobility.

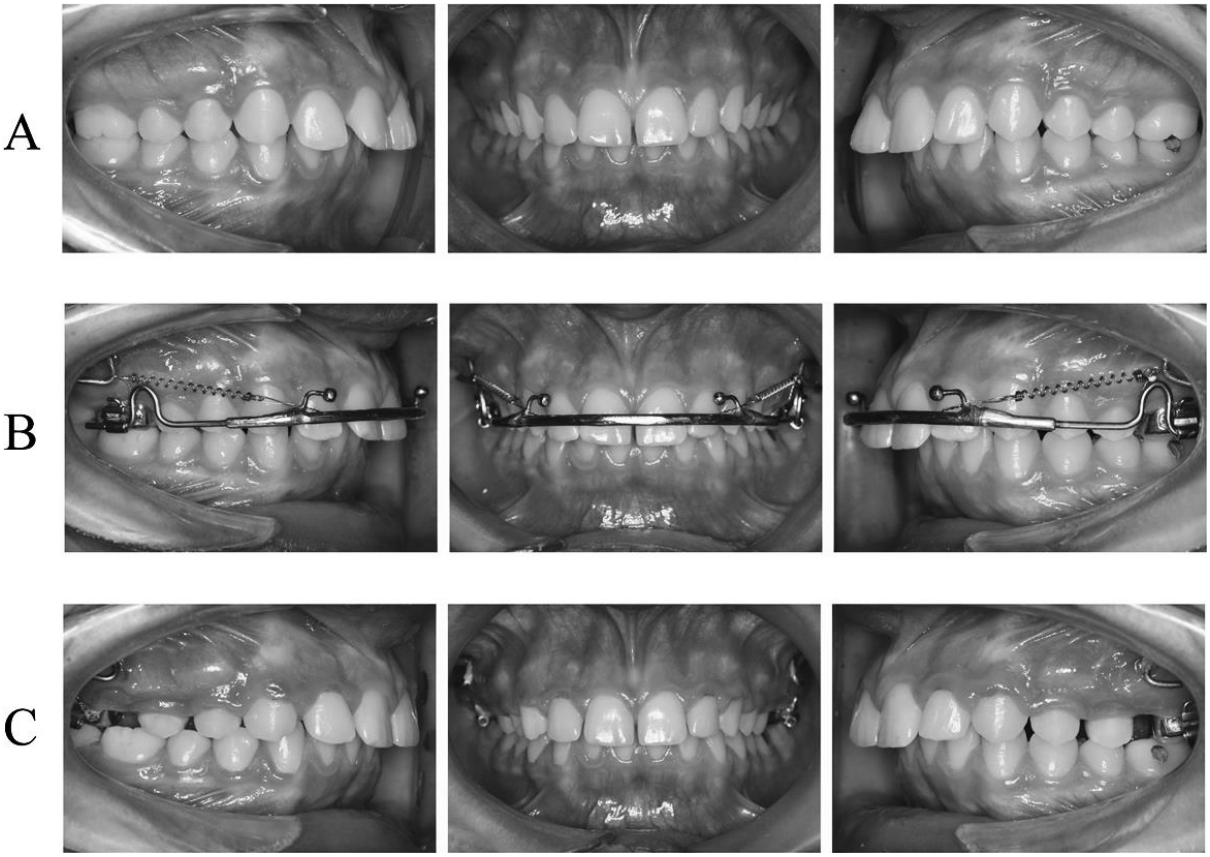

Figure 2: Intraoral photographs of a patient before (A), during (B), and immediately after (C) the distalization.

Zygoma-gear appliance and fixed appliances, Class I molar and canine relationships were established with satisfactory interdigitation of the posterior teeth. Acceptable overjet and overbite were also achieved (**Figure 3**). The palatal implants must be removed and the distalized molars are used as part of the anchorage during retraction of the anterior teeth. Therefore, the reinforcement of molar anchorage or the use of another anchorage area is required to prevent the relapse of molars. The zygomatic process of the maxilla can be used for this purpose because zygomatic anchors can be positioned at the zygomatic buttress, at a safe distance from the roots of the maxillary molars and allow a full unit buccal segment distalization [8, 21].

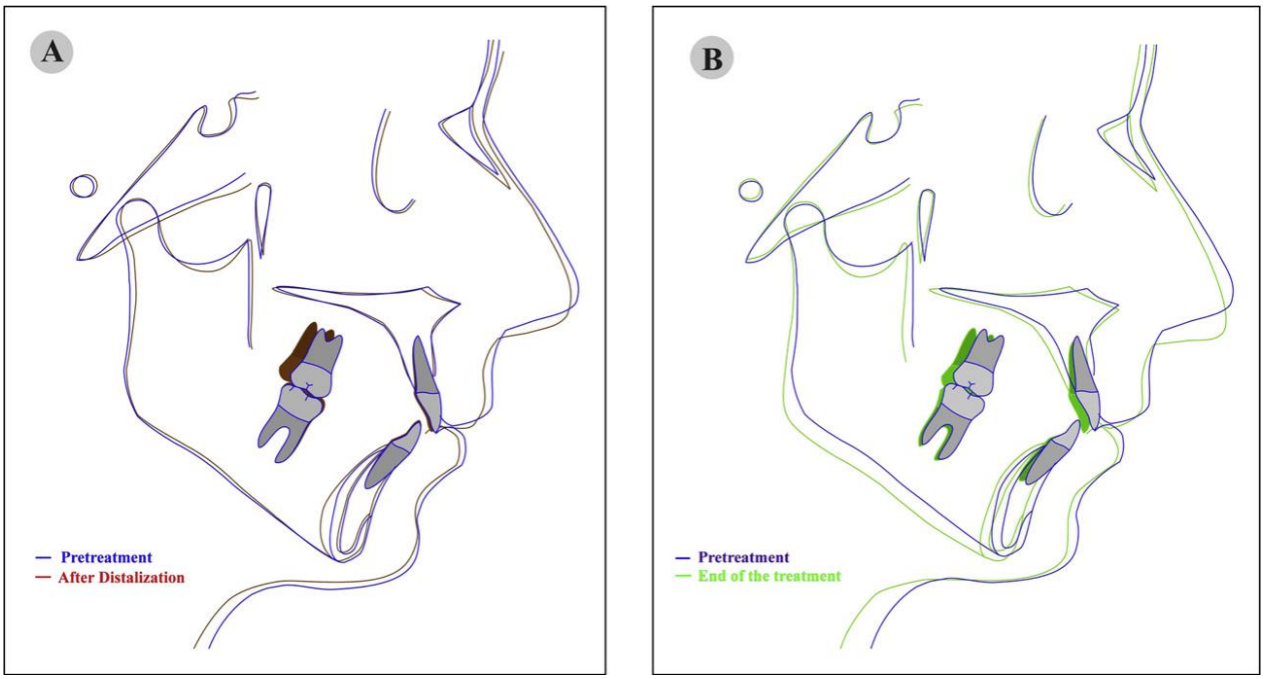

Figure 3: Superimpositions of A, predistalization and postdistalization cephalometric tracings and B, pretreatment and posttreatment cephalometric tracings

CONCLUSION:

Several methods have been used for molar distalization, including headgear, distal jet, and Keles slider. The effects of the different mechanics for molar distalization on the craniofacial complex have been evaluated in several experimental and clinical studies. Evidence have shown that extraoral cervical traction requires considerable patient are more safe with the zygoma-gear appliance with zygomatic anchorage miniplates for unilateral maxillary molar distalization.

REFERENCES:

1. Nalcaci, R., A. A. Biçakçi, and F. Ozan. Noncompliance screw supported maxillary molar distalization in a parallel manner. Korean J Orthod 2010. 40:250–259.
2. Baldini, G. Unilateral headgear: lateral forces as unavoidable side effects. Am J Orthod 1980. 77:333–340.
3. Keles, A. Maxillary unilateral molar distalization with sliding mechanics: a preliminary investigation. Eur J Orthod 2001. 23:507–515.
4. Altug H, Bengi AO, Akin E, Karacay S. Dentofacial effects of asymmetric headgear and cervical headgear with removable plate on unilateral molar distalization. Angle Orthod 2005;75:584-92.
5. Wohl TS, Bamonte E, Pearson HE. Nonextraction treatment of unilateral Class II, Division 1 malocclusion with asymmetric headgear. Am J Orthod Dentofacial Orthop 1998;113:483-7.
6. Nur M, Bayram M, Celikoglu M, Kilkis D, Pampu AA. Effects of maxillary molar distalization with zygoma-gear appliance. Angle Orthod 2012;82:596-602.
7. Kircelli BH, Pektas ZO, Kircelli C. Maxillary molar distalization with a bone-anchored pendulum appliance. Angle Orthod 2006;76: 650-9. 14. Bayram M, Nur M, Kilkis D. The frog appliance for upper molar distalization: a case report. Korean J Orthod 2010;40:50-60.
8. Kaya B, Arman A, Uckan S, Yazici AC. Comparison of the zygoma anchorage system with cervical headgear in buccal segment distalization. Eur J Orthod 2009;31:417-24.
9. Oncag G, Seckin O, Dincer B, Arikan F. Osseointegrated implants with pendulum springs for maxillary molar distalization: a cephalometric study. Am J Orthod Dentofacial Orthop 2007;131:16-26.
10. Fortini, A., M. Lupoli, and M. Parri. The First Class Appliance for rapid molar distalization. J Clin Orthod 1999. 33:322–328.
11. Bayram, M., M. Nur, and D. Kilkis. The frog appliance for upper molar distalization: a case report Korean J Orthod. 2010. 40:50–60.
12. Blechman, A. M. Magnetic force systems in orthodontics. Clinical results of a pilot study. Am J Orthod 1985. 87:201–210.

13. Ngantung, V., R. S. Nanda, and S. J. Bowman. Posttreatment evaluation of the distal jet appliance. Am J Orthod Dentofacial Orthop 2001. 120:178–185.
14. Liou, E. J., B. C. Pai, and J. C. Lin. Do miniscrews remain stationary under orthodontic forces? Am J Orthod Dentofacial Orthop 2004. 126:42–47.
15. Kinzinger, G., N. Gulden, F. Yildizhan, B. Hermanns-Sachweh, and P. Diedrich. Anchorage efficacy of palatally-inserted miniscrews in molar distalization with a periodontally/miniscrew-anchored distal jet. J Orofac Orthop 2008. 69:110–120.
16. Sugawara, J., R. Kanzaki, I. Takahashi, H. Nagasaka, and R. Nanda. Distal movement of maxillary molars in nongrowing patients with the skeletal anchorage system. Am J Orthod Dentofacial Orthop 2006. 129:723–733.
17. Gelgor, I. E., T. Buyukyilmaz, A. I. Karaman, D. Dolanmaz, and A. Kalayci. Intraosseous screw-supported upper molar distalization. Angle Orthod 2004. 74:838–850.
18. Oberti, G., C. Villegas, M. Ealo, J. C. Palacio, and T. Baccetti. Maxillary molar distalization with the dual-force distalizer supported by mini-implants: a clinical study. Am J Orthod Dentofacial Orthop 2009. 135:282. e1–5.
19. Karlsson, I. and L. Bondemark. Intraoral maxillary molar distalization. Angle Orthod 2006. 76:923–929.
20. Yamada, K., S. Kuruda, T. Deguchi, T. T. Yamamoto, and T. Yamashiro. Distal movement of maxillary molars using miniscrew anchorage in the buccal interradicular region. Angle Orthod 2009. 79:78–84.
21. Burstone CJ. Application of bioengineering to clinical orthodontics. In: Graber TM, Vanarsdall RJ editors. Orthodontics. Current principles and techniques. 3rd ed. St Louis: CV Mosby; 2000. p. 259-92