



CODEN [USA]: IAJPBB

ISSN : 2349-7750

**INDO AMERICAN JOURNAL OF
PHARMACEUTICAL SCIENCES**

SJIF Impact Factor: 7.187

<https://doi.org/10.5281/zenodo.7258668>Available online at: <http://www.iajps.com>

Case Study

**ROLE OF CHEST SONOGRAPHY IN DIAGNOSING
PNEUMOTHORAX: A CASE STUDY**

Ahmad Bin Khalid

Sheikh Zayed Medical College Rahim Yar Khan

Article Received: October 2022

Accepted: October 2022

Published: October 2022

Abstract:

Introduction: The use of ultrasound (US) in the diagnosis and treatment of patients is a well-established modality that has existed for many years. **Objectives of the study:** The main objective of the study is to find the role of chest sonography in diagnosing pneumothorax. **Key issues:** This case study was conducted in Jinnah Hospital, Lahore during July 2022. The data was collected from 10 patients with clinical and/or radiographic suspicion of pneumothorax; and patients with chest tube in-situ who required evaluation for residual pneumothorax. **Results:** The data was collected from 10 patients. The duration of complaints ranged from 1 hour to 1 month. On examination, evidence of chest trauma was seen in 7 (70%) cases. Mild subcutaneous emphysema was seen in 3 (30%) cases. Significant general physical examination findings were tachypnoea, fever, tachycardia and lymphadenopathy. **Conclusion:** It is concluded that chest ultrasonography can be used as a primary imaging modality for the diagnosis of pneumothorax in a vast array of clinical settings, as it has a high sensitivity and specificity.

Corresponding author:

Ahmad Bin Khalid,

Sheikh Zayed Medical College Rahim Yar Khan

QR code



Please cite this article in Ahmad Bin Khalid, *Role Of Chest Sonography In Diagnosing Pneumothorax: A Case Study.*, Indo Am. J. P. Sci, 2022; 09(10).

INTRODUCTION:

The use of ultrasound (US) in the diagnosis and treatment of patients is a well-established modality that has existed for many years. Thoracic sonography is fairly new in comparison to other accepted ultrasound applications, and is still rapidly evolving. The use of thoracic ultrasound has gained slow acceptance due to the traditional teaching that the air-filled lungs are not ultrasound friendly [1]. Poor imaging is a result of the confinement of air between the lung and the chest wall, preventing diffusion of the ultrasound beam into the parietal pleura and deep lung structures, leading to a production of artifacts [2].

Over the past decade, bedside lung sonography has developed an established role in literature for the diagnosis of thoracic diseases. This development is based on an improved understanding and appreciation of the sonographic artifacts created by the interplay of air and fluid in the lungs. The first reported use of ultrasound to detect pneumothorax in humans was by Wernecke *et al.*, in 1987 [3]. The Focused Assessment with Sonography in Trauma (FAST) examination has now been modified to include lung imaging as part of the evaluation in a trauma patient. The application has been renamed as the E-FAST examination, with 'E' standing for extended, including the standard lung views [4].

Thoracic cavity injuries include 25% of mortalities in traumatic events and are associated with a 40% mortality rate, generally. Studies have shown that early diagnosis of such traumas can decrease the mortality rate and the resultant burden, significantly. CT scan with a high priority for detection of chest traumas is the gold standard for diagnosis of thoracic traumas [5]. Although this diagnostic test has high accuracy, patients undergoing CT scan receive a high radiation dose; thus, it is recommended to use this test only when it is indicated. In addition, CXR is used as the early diagnostic test in patients with thoracic injuries, yet the accuracy of it is not very high [6].

A pneumothorax can be divided into two broad categories: traumatic (including iatrogenic) or atraumatic. Atraumatic pneumothorax can further be categorized as primary spontaneous or secondary

spontaneous. Pneumothorax is commonly associated with both blunt and penetrating chest injury and is a leading cause of preventable morbidity and mortality. Traumatic pneumothorax, the most common life-threatening outcome in blunt chest trauma, occurs in over 20% of patients with blunt injuries and about 40% with penetrating chest injuries [7].

Outline of the purpose

The main objective of the study is to find the role of chest sonography in diagnosing pneumothorax.

Key issues

This case study was conducted in Jinnah Hospital, Lahore during July 2022. The data was collected from 10 patients with clinical and/or radiographic suspicion of pneumothorax; and patients with chest tube in-situ who required evaluation for residual pneumothorax.

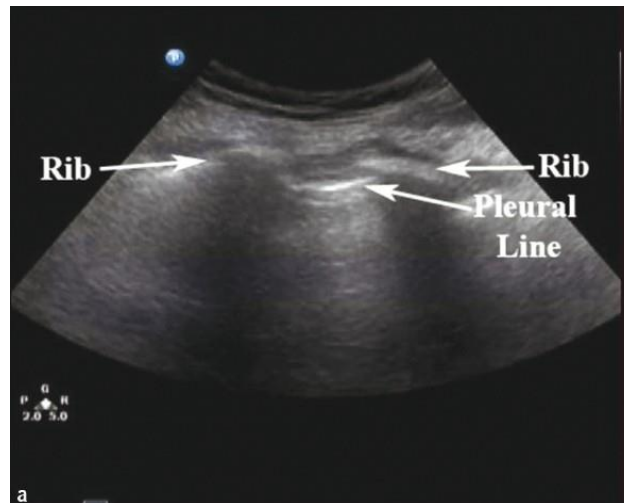
Case description

Patients with extensive subcutaneous emphysema were excluded from the study. Findings were recorded in a proforma and a video recording was also made on the ultrasonography machine. Both sides of the thorax were evaluated, starting with the unaffected lung, to establish a baseline. Chest radiograph was obtained in supine or erect position within 30 minutes of performing chest ultrasonography.

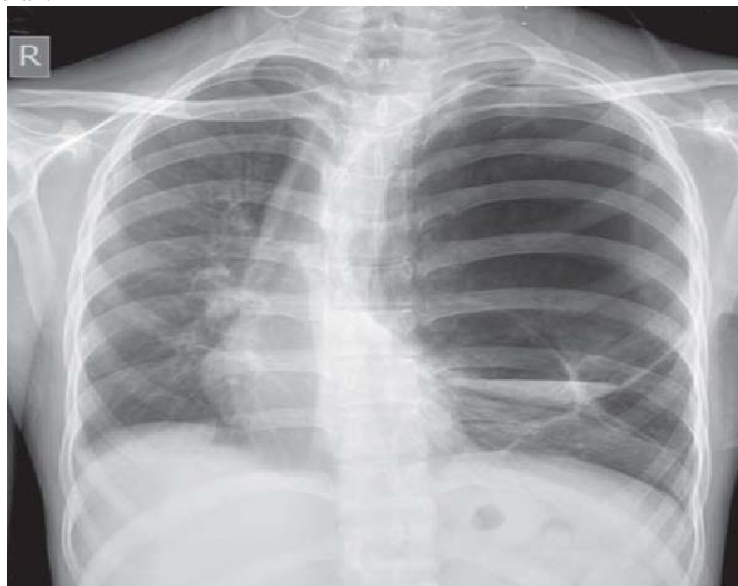
The sensitivity, specificity, positive predictive value (PPV), negative predictive value (NPV) and overall accuracy of chest ultrasonography were calculated considering using radiograph.

Findings

The data was collected from 10 patients. The duration of complaints ranged from 1 hour to 1 month. On examination, evidence of chest trauma was seen in 7 (70%) cases. Mild subcutaneous emphysema was seen in 3 (30%) cases. Significant general physical examination findings were tachypnoea, fever, tachycardia and lymphadenopathy. Pneumothorax was diagnosed by chest ultrasonography in 9/10 confirmed cases of pneumothorax (true-positive). Chest ultrasonography was able to diagnose all the 9 cases in whom therapeutic intervention was needed for the management of pneumothorax.



Parallel horizontal hyperechoic lines (arrows), which show immobility during breathing movements, suggest a diagnosis of pneumothorax.



Chest radiograph (postero-anterior view) of 1 patient showing a large infected bulla in the left lung which mimicked pneumothorax on ultrasonography.

Table 01: Comparison of the AUC-ROC of Clinical Examination + CXR vs Thoracic Ultrasonography for detecting pneumothorax.

	CXR + Clinical examination		U/S		Z test	P value
	AUC (CI: 95%)	SE	AUC (CI: 95%)	SE		
Pneumothorax	0.98 (0.93–1.02)	0.02	0.97 (0.92–1.01)	0.02	0.31	0.749

DISCUSSION:

Thoracic sonography for the detection of pneumothorax has become a well-established modality in the acute care setting. It is indispensable in the blunt or penetrating chest trauma patient, where the identification of a pneumothorax can prevent life-threatening consequences. The ease of use and portability of newer machines, combined with the improved training among physicians has allowed

thoracic ultrasound to become a useful bedside tool in patients with respiratory complaints [8]. The traditional upright AP radiograph has become less important due to its poor sensitivity in diagnosing a pneumothorax compared to ultrasound. Although CT scan remains the gold standard and may still catch smaller occult pneumothoraxes that ultrasound misses, its disadvantages are becoming more apparent [9]. Bedside ultrasound obviates the need for patient

transport in unstable situations, it eliminates radiation exposure, it is quicker to perform and is immediately interpreted at the bedside without unnecessary delays. In addition, it is more cost-effective and can be repeated multiple times during a resuscitation [10].

In addition, ultrasound is the perfect modality in the emergency and critical care setting after performing certain procedures, such as a thoracentesis or the placement of a central line, to quickly confirm the presence of lung-sliding and to rule out an iatrogenic pneumothorax [11]. It has also been found to be beneficial in the post-intubation scenario, where a confirmation of bilateral lung sliding rules out a right mainstem intubation [12].

CONCLUSION:

It is concluded that chest ultrasonography can be used as a primary imaging modality for the diagnosis of pneumothorax in a vast array of clinical settings, as it has a high sensitivity and specificity.

REFERENCES:

1. Bridges KG, Welch G, Silver M, Schinco MA, Esposito B. CT detection of occult pneumothorax in multiple trauma patients. *J Emerg Med.* 1993;11:179–86.
2. Kirkpatrick AW, Sirois M, Laupland KB, Liu D, Rowan K, Ball CG, et al. Hand-held thoracic sonography for detecting post-traumatic pneumothoraces: The extended focused assessment with sonography for trauma (EFAST) *J Trauma.* 2004;57:288–95.
3. Ball CG, Ranson K, Dente CJ, Feliciano DV, Laupland KB, Dyer D, et al. Clinical predictors of occult pneumothoraces in severely injured blunt polytrauma patients: A prospective observational study. *Injury.* 2009;40:44–7.
4. Ball CG, Kirkpatrick AW, Laupland KB, Fox DI, Nicolaou S, Anderson IB, et al. Incidence, risk factors, and outcomes for occult pneumothoraces in victims of major trauma. *J Trauma.* 2005;59:917–25.
5. Blaivas M, Lyon M, Duggal S. A prospective comparison of supine chest radiography and bedside ultrasound for the diagnosis of traumatic pneumothorax. *Acad Emerg Med.* 2005;12:844–9.
6. Dulchavsky SA, Schwarz KL, Kirkpatrick AW, Billica RD, Williams DR, Diebel LN, et al. Prospective evaluation of thoracic ultrasound in the detection of pneumothorax. *J Trauma.* 2001;50:201–5.
7. Zhang M, Liu ZH, Yang JX, Gan JX, Xu SW, You XD, et al. Rapid detection of pneumothorax by ultrasonography in patients with multiple trauma. *Crit Care.* 2006;10:R112.
8. Tocino IM, Miller MH, Frederick PR, Bahr AL, Thomas F. CT detection of occult pneumothorax in head trauma. *AJR Am J Roentgenol.* 1984;143:987–90.
9. Soldati G, Testa A, Sher S, Pignataro G, La Sala M, Silveri NG. Occult traumatic pneumothorax: Diagnostic accuracy of lung ultrasonography in the emergency department. *Chest.* 2008;133:204–11.
10. Lichtenstein DA, Menu Y. A bedside ultrasound sign ruling out pneumothorax in the critically ill. Lung sliding. *Chest.* 1995;108:1345–8.
11. Tocino IM, Miller MH, Fairfax WR. Distribution of pneumothorax in the supine and semirecumbent critically ill adult. *AJR Am J Roentgenol.* 1985;144:901–5.
12. Ball CG, Kirkpatrick AW, Laupland KB, Fox DL, Litvinchuk S, Dyer DM, et al. Factors related to the failure of radiographic recognition of occult posttraumatic pneumothoraces. *Am J Surg.* 2005;189:541–6.