



CODEN [USA]: IAJPB

ISSN : 2349-7750

**INDO AMERICAN JOURNAL OF
PHARMACEUTICAL SCIENCES**

SJIF Impact Factor: 7.187

<https://doi.org/10.5281/zenodo.8165155>Available online at: <http://www.iajps.com>

Research Article

**EVALUATION OF ANTIACNE ACTIVITY OF A MARKETED
ANTIACNE GEL ON SYRIAN GOLDEN HAMSTERS**¹Srivatsavai Lakshmi Sandili, ²Sunkara Anju Sree, ³Tapa Poojitha, ⁴Telepalli Haritha,
⁵Telikicherla Veenapani, ⁶Vantakula Lavanya, ⁷Koyya Roshini, ⁸Chandaka Madhu¹Avanthi Institute Of Pharmaceutical Sciences, Cherukupally, Near Tagarapuvalasa Bridge,
Vizianagaram – 531162 AP, India.

Article Received: April 2023

Accepted: May 2023

Published: June 2023

Abstract:

Acne vulgaris is a multifactorial disease of the pilosebaceous unit. Acne is mainly caused due to androgen-mediated stimulation of sebaceous gland activity, abnormal keratinization leading to follicular plugging (comedo formation), proliferation of the bacterium Propionibacterium acnes within the follicle, and inflammation. In addition to these, genetic factors, stress, and possibly diet may also influence the development and severity of acne. Common therapies that are used for the treatment of acne include topical, systemic, hormonal, herbal and combination therapy. Topically used agents are benzoyl peroxide, antibiotics and retinoid. Systemically used agents are antibiotics and isotretinoin. The present study was conducted to evaluate the anti-acne activity of a marketed herbal anti acne gel on hamster ear and flank organ model. The dose required to induce sebaceous gland hyperplasia was evaluated in both male and female hamsters. The herbal anti acne gel did not produce any skin irritation on the ears and flank organs of hamsters when applied for 24 days. The herbal anti acne gel showed a significant decrease in the size of sebaceous glands of ear and the effect is comparable to the standard drug spironolactone. The present study indicates the sebaceous gland modulation potential of marketed herbal gel for anti ACNE activity.

Keyword: sebaceousglands, propionibacterium, spironolactone, hamsters**Corresponding author:****Chandaka Madhu,**

Asst.prof, Dept of pharmacology

Email id: pharmamadhuphd@gmail.com

QR code



Please cite this article in press Chandaka madhu et al, *Evaluation Of Antiacne Activity Of A Marketed Antiacne Gel On Syrian Golden Hamsters.*, Indo Am. J. P. Sci, 2023; 10 (06).

INTRODUCTION:

Skin is perhaps the most vulnerable part of our body. It is well-known fact that day to day exposure of human skin lead to number of problems such as acne, pimples, pigmentation and sun burn marks. Acne is one of the most common skin diseases¹. It is a chronic inflammatory disease of the pilosebaceous unit, mostly affecting the sebaceous gland follicles, exclusively affecting human beings². It is a pleomorphic disorder and can manifest at any time during life³. Acne develops earlier in females, usually at about 12 or 13 years, than in males, 14 or 15 years, due to the earlier onset of puberty in females and the Severity of the disease vary depending on the various factors⁴. Acne is a group of disorders that causes outbreaks of skin lesions commonly called pimples factors which contribute to the development of acne include hormonal imbalance, bacterial infection, stress, food, or cosmetic application additionally some species of *Propionibacterium* are found in milk and cheese and some time in other agricultural product⁵. In regard to gender, acne is significantly higher among women than men in all age groups⁶. The main causes of acne may include hormones and genetics while it also can be occurred due to some medication especially those containing iodides, bromides, or oral or injected steroids, cosmetics, chemicals, pressure, occupation & diet as well as environmental factors which can work as catalyst⁴. Common therapies that are used for treatment of acne include topical, systemic, hormonal, herbal and combinational therapy⁷. Topically used agents generally used are benzoyl peroxide, antibiotics and retinoids. Systemically used agents are antibiotics and isotretinoin.

According to Ayurveda, ACNE is caused due to excess of pitta. Therefore, Ayurveda approaches acne from symptomatic and causative levels to remove symptoms, herbs and herbal preparations can be used. Simultaneously, the excess pitta and toxins inside the

body should be reduced. If neglected, pitta and toxins cause the reappearance of acne or manifests as illness in another part of the body⁸. Herbal extracts or oil can be used as monotherapy or in combination therapy. Standardization of methods, quality control data on safety and efficacy are need for proper understanding for the use of herbal medicines

The present study shows the anti-acne property of tea tree oil (*Melaleuca alternifolia*) in female hamsters. Tea tree oil is known to be effective in treatment of acne vulgaris. Applying a 5% tea tree oil gel appears to be as effective as 5% benzoyl peroxide for treating acne. Tea tree oil might work slowly than benzoyl peroxide, but is less irritating to skin³⁵.

Description of melaleuca alternifolia⁹:

Tea tree oil (TTO), is the volatile essential oil derived mainly from the Australian native plant *Melaleuca alternifolia*. It is employed largely for its antimicrobial properties; TTO is incorporated as the active ingredient in many topical formulations used to treat cutaneous infections. It is widely available over the counter in Australia, Europe, and North America and is marketed as a remedy for various ailments.

Composition and chemistry of tea tree oil:

TTO is composed of terpene hydrocarbons, mainly monoterpenes, sesquiterpenes, and their associated alcohols. Terpenes are volatile, aromatic hydrocarbons and may be considered polymers of isoprene, which has the formula C₅H₈. Based on gas chromatography and gas chromatography- mass spectroscopy studies it was found that approximately 100 components and their ranges of concentrations are seen in TTO.

Tea tree oil has a relative density of 0.885-0.906. it is sparingly soluble in water and is miscible with non-polar solvents

TABLE 1. Composition of *M. alternifolia*(tea tree) oil

component	Concentration(%)	
	ISO 4730 range a	Typical composition b
Terpinen-4-ol	≥ 30 c	40.1
γ-Terpinene	10-28	23
α-Terpinene	5-13	10.4
1,8 Cineole	≤15d	5.1
Terpinolene	1.5-5	3.1
p-Cymene	0.5-12	2.9
α- Pinene	1-6	2.6
α-Terpineol	1.5-8	2.4
Aromadendrene	Trace- 7	1.5
δ-Cadinene	Trace-8	1.3
limonene	0.5-4	1
Sabinene	Trace-3.5	0.2
Globulol	Trace-3	0.2
Viridiflorol	Trace-1.5	0.1

MATERIALS AND METHODS:

Extraction of tto oil:

TTO is produced by steam distillation of the leaves and terminal branches of *M. alternifolia*. Once condensed, the clear to pale yellow oil is separated from the aqueous distillate. The yield of oil is typically 1 to 2% of wet plant material weight. Alternative extraction methods such as the use of microwave technology have been considered, but none has been utilized on a commercial scale.

Safety and toxicity of tto oil:

Despite the progress in characterizing the antimicrobial and anti-inflammatory properties of tea tree oil, less work has been done on the safety and toxicity of the oil. The rationale for continued use of the oil rests largely on the apparently safe use of the oil for almost 80 years. Anecdotal evidence over this time suggests that topical use is safe and that adverse events are minor, self-limiting, and infrequent. More concrete evidence such as published scientific work is scarce, and much information remains out of the public domain in the form of reports from company-sponsored work.

Objective:

1. To evaluate and compare marketed herbal anti-acne formulation for anti-ACNE

Reagents:

Alcohol : water (4 :1)

Testostérone propionate (IPCA laboratoires, TP/M/004/11)

potential in hamster ear and flank organ model.

- Analyzing the size of sebaceous glands in the ears of the normal male and female hamsters.
- Establishing the method (stripped skin planimetry) to evaluate and measure the sebaceous glands in hamster ear model.
- Establish the relation between stimulation of androgens and sebum production using testosterone propionate.

Animals:

Syrian golden hamsters male and female animals were used for the study procured from NIPER, Mohali and acclimatized to experimental room for 2 weeks before the experiment. The experiments were performed with hamsters at 9-10 weeks of age in accordance with institute of animal ethics committee (ref no:3/1999/cpcesa,15october,2009). The animals were placed in laboratory cages, and Cage card indicating number of animals; animal number and different dose group were attached. The animals were fed with NIN powder and pellet feed and RO water was provided ad libitum in polypropylene bottles freshly filled twice a week.

Spirolactone (Sigma, S-3378, Lot : 071M1669V)
 SesameOil (Sigma, S3547, Lot#MKBF48)
 Lotus anti acne gel (lotus herbals,Noida)

Preparation of testosterone propionate^{10,11,12}:
 100µg and 500µg will be dissolved in 100µL sesame oil and injected subcutaneously alternate days for a period of 2 weeks to stimulate androgen response.

Preparation of Spirolactone solution¹³:

14 mg of Spirolactone dissolved in 280 µl of Ethanol + water vehicle (1mg/kg)

Ethanol+ water vehicle preparation: 0.8 ml of Ethanol mixed with 0.2ml M.Q water

Active ingredients of lotus anti acne gel: Tea tree oil

METHODS:

Study 1:

Analyzing the area of sebaceous glands in the ears of the normal male and female hamsters.

1 male and 1 female hamster was taken for study. They were sacrificed by CO₂ asphyxia. The ears were collected by cutting at the base and stored in 10%NBF separately. The sebaceous glands in the ears were then observed by stripped skin planimetry and measured using image analyzer software.

Establishing the method (stripped skin planimetry) to evaluate and measure the sebaceous glands in hamster ear model.

Stripped skin planimetry is a method developed to measure the ear sebaceous gland areas. The ear skin was manually separated from the cartilage and observed under a microscope. Using stripped skin planimetry, it was demonstrated that the sebaceous gland size was greatest at the basal region of the ear and decreased towards the apex. The regional variations in densities of sebaceous glands were also observed.

PROCEDURE:

Hamsters were sacrificed and the ears were removed by cutting at the base using surgical scissors. The dorsal ear skin was gently pulled away from the supporting cartilage, starting at the base and extending towards the apex of ear. The stripped skin was placed in 0.9% saline with the epidermal side facing the bottom of the dish. The cartilage was gently scrapped off with a scalpel. After rinsing with saline, the ears were fixed in neutral buffered formalin (NBF). Three distinct zones were collected at the midline of the ear.

- The apical zone-extends from apex to 3mm
- The medial zone-extends from apex to 5-8mm
- The basal zone-extends from apex to 10-13mm

The dermis of the skin was sufficiently thin after removal of cartilage from the ear skin to allow direct observation of each sebaceous gland unit without the need for staining. The stripped skin was placed under microscope and measured by whole mount technique. The average diameter of the sebaceous gland was measured using NIKON ACT 1 microscope.

The densities of the sebaceous glands in different zones were calculated in 1 sq mm area.

The areas of 10 sebaceous glands were calculated using image analyzer software.

Study 2:

Evaluation of sebaceous gland size and the effect of testosterone propionate to stimulate androgen response in female hamsters:

About 16 female Syrian golden hamsters were taken for the study. The animals were divided into 3 groups. Group 1 contains 4 animals; they were treated with vehicle (sesame oil) subcutaneous injections alternate days for 2 weeks. Group 2 and group 3 contain 6 animals each. They were treated with testosterone propionate 1 mg/kg and 5 mg/kg subcutaneous injections alternate days for 2 weeks respectively.

Group 1:- Vehicle (Sesame oil) (n=4)

Group 2:- 1mg/kg S.C. Testosterone propionate alternate days for 2 weeks (n=6)

Group 3:- 5 mg/kg S.C. Testosterone propionate alternate days for 2 weeks (n=6)

DOSE VOLUME:- 2ml/kg

On day 15 the animals were sacrificed under CO₂ asphyxia. The ears were collected by cutting at the base and stored in 10%NBF. The sebaceous glands in the ears were then observed by stripped skin planimetry and measured using image analyzer software.

Evaluation of sebaceous gland size and the effect of testosterone propionate to stimulate androgen response in male hamsters:

About 10 male Syrian golden hamsters were taken for the study. The animals were divided into 3 groups. Group 1 contains 2 animals; they were treated with vehicle (sesame oil) subcutaneous injections alternate days for 2 weeks. Group 2 and group 3 contain 4 animals each. They were treated with Testosterone propionate 1 mg/kg and 5 mg/kg

subcutaneous injections alternate days for 2 weeks respectively.

Group 1:- Vehicle (Sesame oil) (n=2)

Group 2:- 1mg/kg S.C. Testosterone propionate alternate days for 2 weeks (n=4)

Group 3:- 5 mg/kg S.C. Testosterone propionate alternate days for 2 weeks (n=4)

DOSE VOLUME: - 2ml/kg

On day 15 the animals were sacrificed under CO₂ asphyxia. The ears were collected by cutting at the base and stored in 10%NBF. The sebaceous glands in the ears were then observed by stripped skin planimetry.

Study 3:

Evaluation of anti acne activity of marketed herbal anti acne gel in male hamsters

About 18 male Syrian golden hamsters were taken for the study. The animals were divided into 3 groups, each group contains 6 animals. The group I was control, treated with Vehicle (ethanol+ water) which was applied to the right ear and right flank organ bis in die (B.I.D). Group II was standard, treated with Spironolactone solution (1 mg/kg) which was applied to the right ear and right flank organ B.I.D. Group III was test, treated with topical herbal anti acne gel (80 mg) which was applied to the right ear and right flank organ B.I.D.

Group I (Control):- Vehicle (Ethanol + water) (n=6)

Group II (Standard):- Topical Spironolactone solution (n=6)

Group III (Test):- Topical herbal anti acne gel (n=6)

On day 6, 12, 18 and 24th the flank organ was traced on an OHP sheet and the area was measured.

Measurement of flank organ¹⁴:

The skin overlying the flank organs was closely shaved on every 3rd day with an electric hair clipper and the visible or palpable bulk of the organs- rather than the area of pigmentation- was traced on an OHP sheet (3mm). The area was then measured by a thin ruler. The largest longitudinal diameter (DL) and the largest transverse diameter (DT) in millimeters were

measured and flank organ size was expressed as the product of **DL × DT** in mm².

On day 24 the animals were sacrificed under CO₂ asphyxia. The ears were collected by cutting at the base and the flank organs separated, stored in 10%NBF. The sebaceous glands in the ears were then observed by stripped skin planimetry.

Assessment of sebaceous glands

- Image was captured using a microscope at (4x) magnification
- The image was analyzed using a image analyzer software
- The number of sebaceous glands in 1mm² area and the size of 10 sebaceous glands were measured.

STATISTICAL ANALYSIS:

The data was analyzed by using graph pad prism. The values of control right ears were compared with standard and test formulations right ear sebaceous gland area by One way ANOVA followed by Dunnett's test.

Contra lateral ear sebaceous glands (left ear) of the 3 groups were compared to the treated right ear sebaceous glands by One way ANOVA followed by Dunnett's test.

The size of the flank organs was calculated every week on day 1,7 and 14.the mean areas of the flank organs of Spironolactone and herbal anti acne gel group were calculated and compared with the flank organs of normal animals by two way ANOVA followed by Bonferroni's test.

RESULTS:

Study1:

The size of the sebaceous glands in the ears of normal, untreated animals was observed by stripped skin planimetry.

The area of sebaceous glands of normal male animals was calculated at the basal, medial and apical regions and it was found to be 0.090 ± 0.002 , 0.085 ± 0.003 , and 0.010 ± 0.002 mm² respectively.The density of sebaceous glands in 1 sq mm area of ear was calculated at the basal, medial and apical regions, it was found to be 6.3 ± 0.9 , 7.3 ± 0.9 , and 15.3 ± 0.7 respectively.

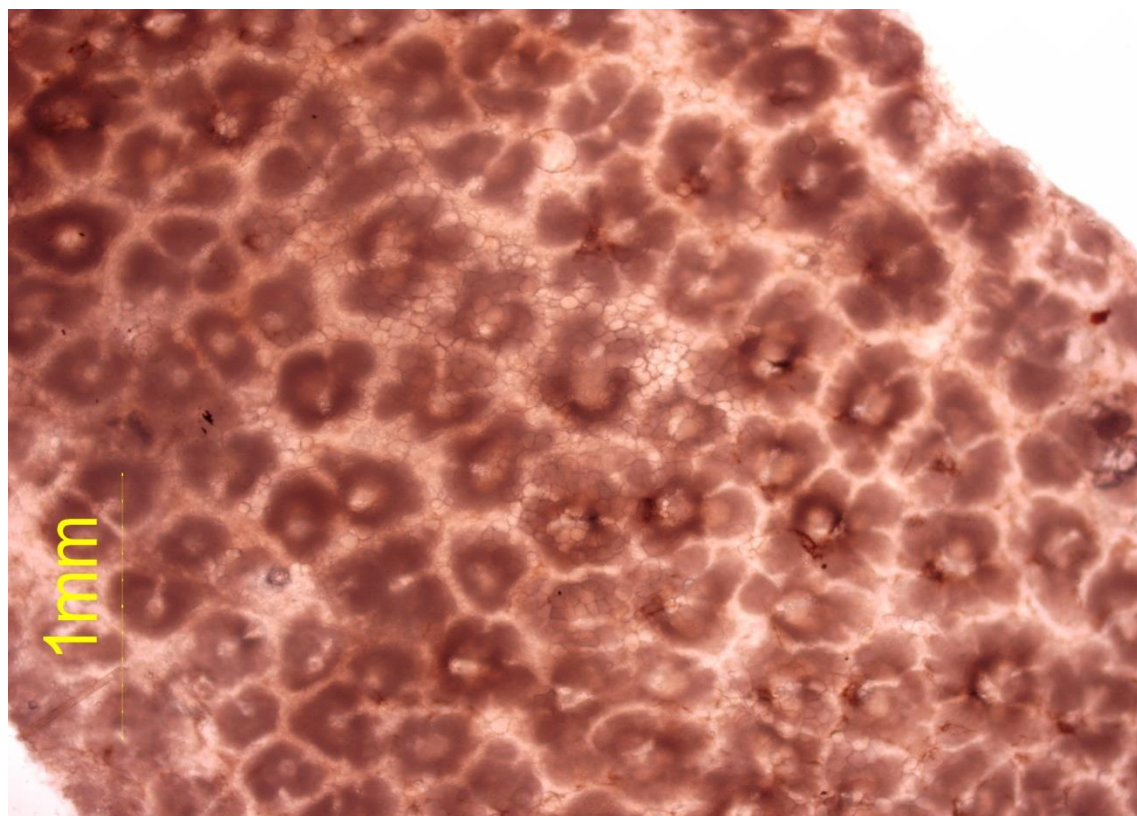


FIGURE 2: Sebaceous glands at the basal region of normal, untreated male hamster ear.

The area of sebaceous glands of normal female animals was calculated at the basal and medial regions and it was found to be 0.021 ± 0.001 , $0.023 \pm 0.001\text{mm}^2$ respectively. The density of sebaceous glands in 1 sq mm area of ear was calculated at the basal, and medial regions, it was found to be 6.3 ± 0.7 , and 6.0 ± 0.6 , and respectively.

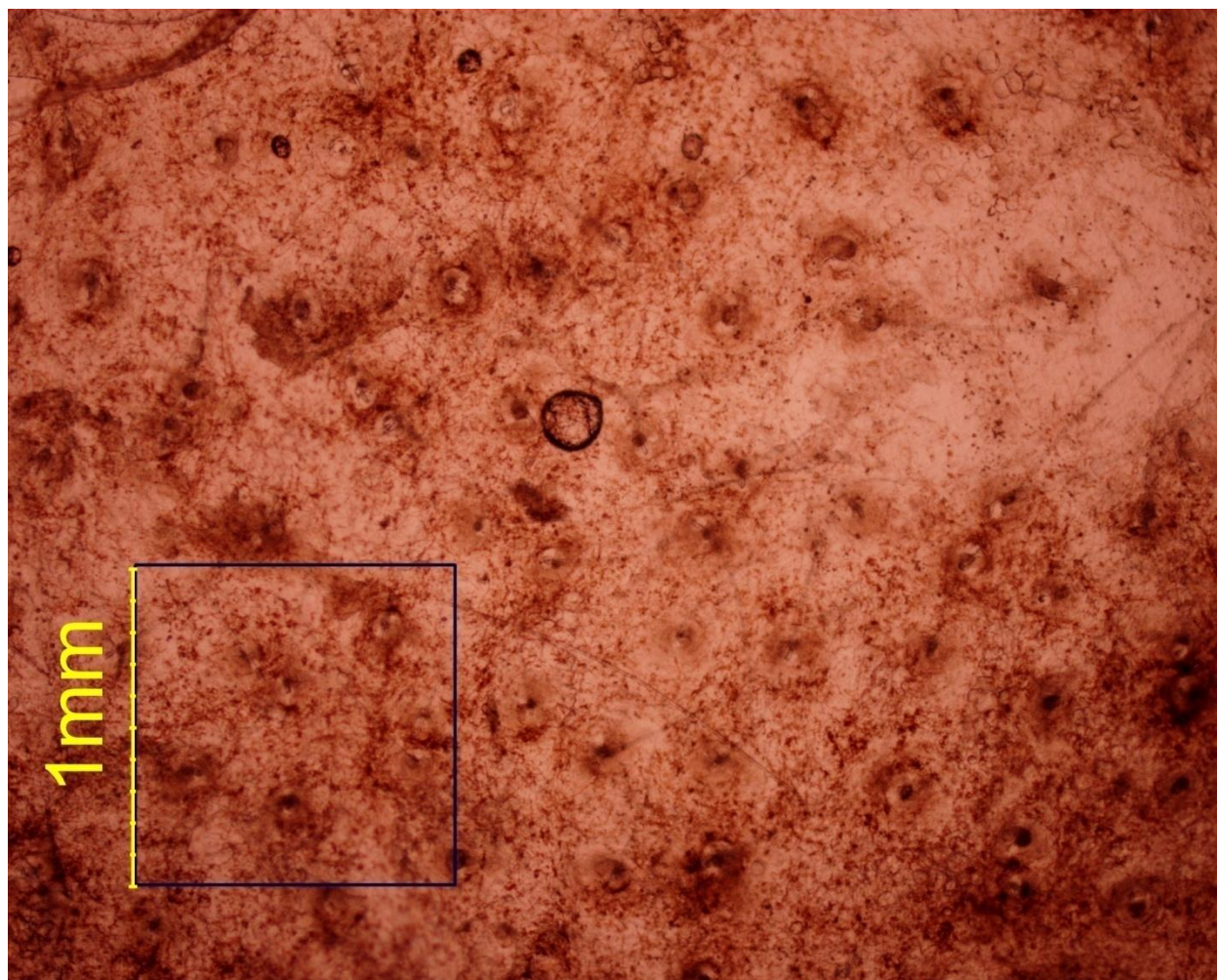


FIGURE 2: Sebaceous glands at the basal region of normal, untreated female hamster ear. STUDY2:

Evaluation of sebaceous gland size and the effect of testosterone propionate to stimulate androgen response in female hamsters:

Testosterone propionate 1 mg/kg and 5mg/kg was injected subcutaneously to the animals, every alternate day for 2 weeks. The increase in the size of sebaceous glands was significant when compared to the control group to which sesame oil was injected every alternate day.

The area of sebaceous glands of normal animals, testosterone propionate (1mg/kg), and testosterone propionate (5mg/kg) was calculated and it was found to be 0.017 ± 0.001 , 0.071 ± 0.003 , and 0.087 ± 0.003 mm² respectively. The density of sebaceous glands in 1 sq mm area of ear was calculated, it was found to be 5.3 ± 0.4 , 5.8 ± 0.3 , and 5.3 ± 0.2 respectively.

Sr. No	Group	Area(mm ²)(Mean \pm SEM)	Fold increase from normal control	Density(Mean \pm SEM)
1.	Normal control N=4	0.017 ± 0.001		5.3 ± 0.4
2.	Testosterone propionate(1mg/kg) N=6	0.071 ± 0.003	~4 fold	5.8 ± 0.3
3.	Testosterone propionate(5mg/kg) N=6	0.087 ± 0.003	~ 5 fold	5.3 ± 0.2

Evaluation of sebaceous gland size and the effect of testosterone propionate to stimulate androgen response in male hamsters

Testosterone propionate 1mg/kg and 5mg/kg was injected subcutaneously to the animals, every alternate day for 2 weeks. There was no significant increase in the size of sebaceous glands of male hamsters on treatment with testosterone propionate.

The area of sebaceous glands of normal animals, testosterone propionate (1mg/kg), and testosterone propionate (5mg/kg) was calculated and it was found to be 0.078 ± 0.002 , 0.115 ± 0.006 and 0.118 ± 0.010 mm² respectively. The density of sebaceous glands in 1 sq mm area of ear was calculated, it was found to be 5.3 ± 0.4 , 5.8 ± 0.3 , and 5.3 ± 0.2 respectively.

The size of sebaceous glands in the animals with 1mg/kg testosterone propionate was about 1.4 times more than the size of sebaceous glands of normal control animals. The size of sebaceous glands in the animals with 5 mg/kg testosterone propionate was about 1.5 times more than the size of sebaceous glands of normal control animals. The density of sebaceous glands in 1 sq mm area of ear was also calculated. There was no significant difference found in the density of sebaceous glands in the treated animals when compared to normal animals.

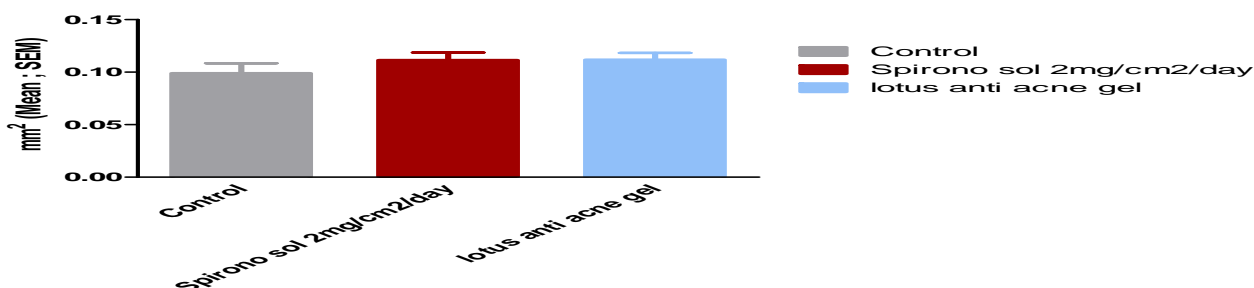
Sl. No	Group	Area(mm ²)(Mean± SEM)	Fold increase from normal control	Density(Mean ± SEM)
1.	Normal control N=2	0.078 ± 0.002		5.3 ± 0.4
2.	Testosterone propionate(1mg/kg) N=4	0.115 ± 0.006	~1.4 fold	5.8 ± 0.3
3.	Testosterone propionate(5mg/kg) N=4	0.118 ± 0.010	~ 1.5 fold	5.3 ± 0.2

STUDY3

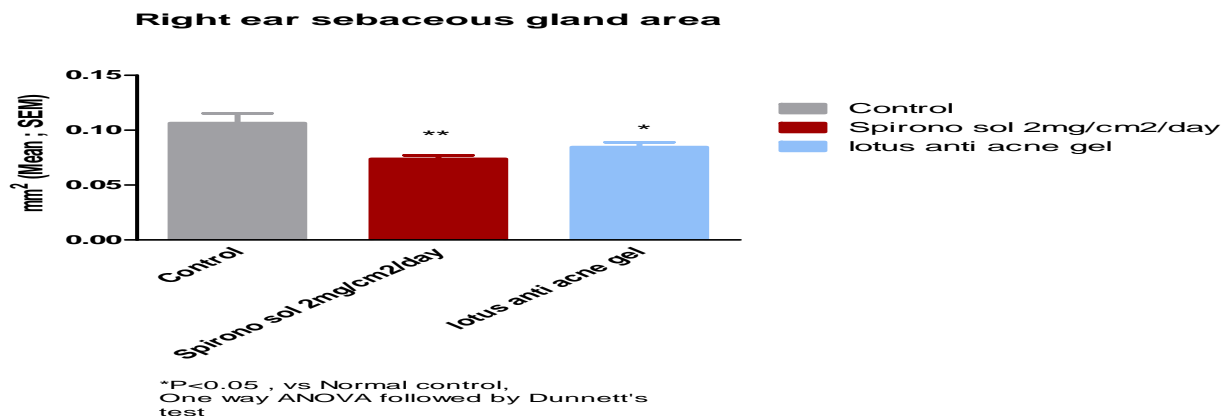
Evaluation of anti-acne activity of marketed herbal anti-acne gel in male hamsters.

The mean area of the sebaceous glands of left ears of control, Spironolactone (1mg/kg), and lotus anti acne gel groups was found to be 0.096 ± 0.008 , 0.112 ± 0.007 , and 0.1119 ± 0.006 .

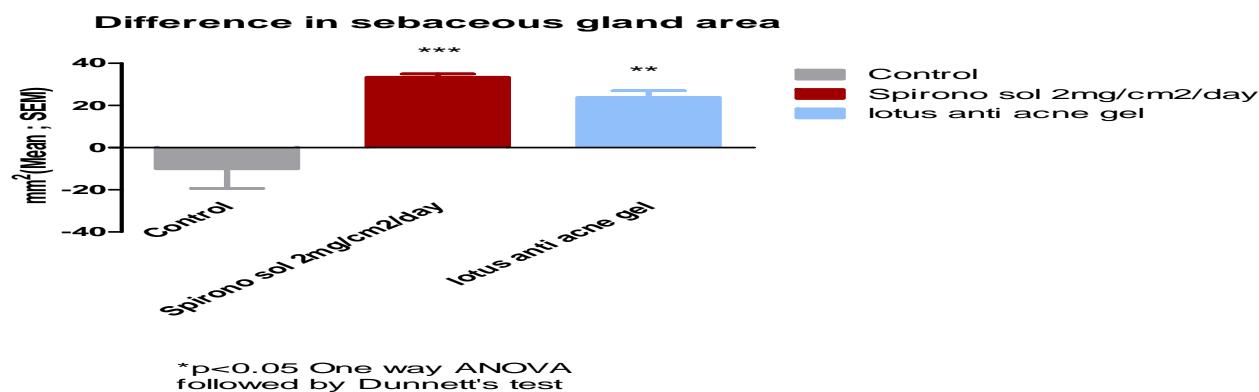
Left ear sebaceous gland area



The mean area of the sebaceous glands of right ears of control, Spironolactone (1mg/kg), and lotus anti acne gel groups was found to be 0.100 ± 0.009 , 0.074 ± 0.003 , and 0.0847 ± 0.004 .

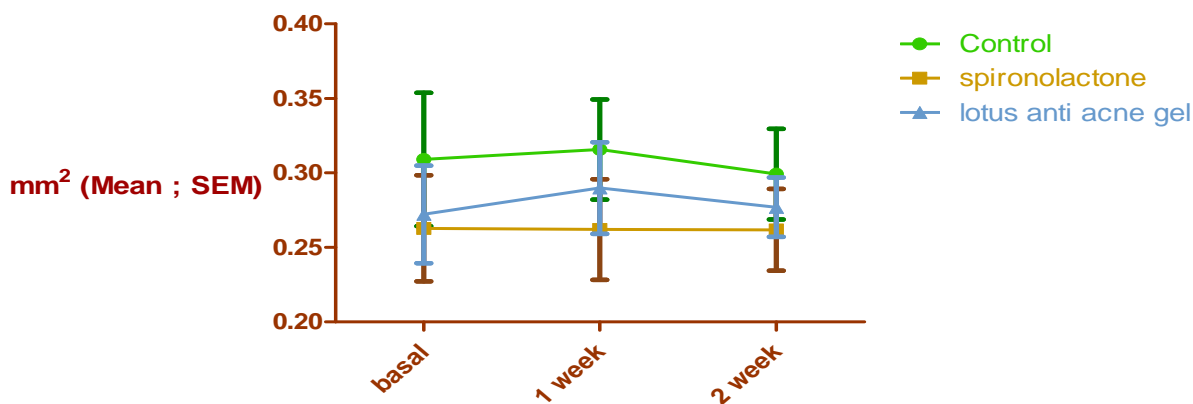


The percentage reduction in the size of sebaceous glands in the right ear when compared to left ear in control, Spironolactone (1mg/kg), and lotus anti acne gel groups was found to be 6%, 33% and 24% respectively.



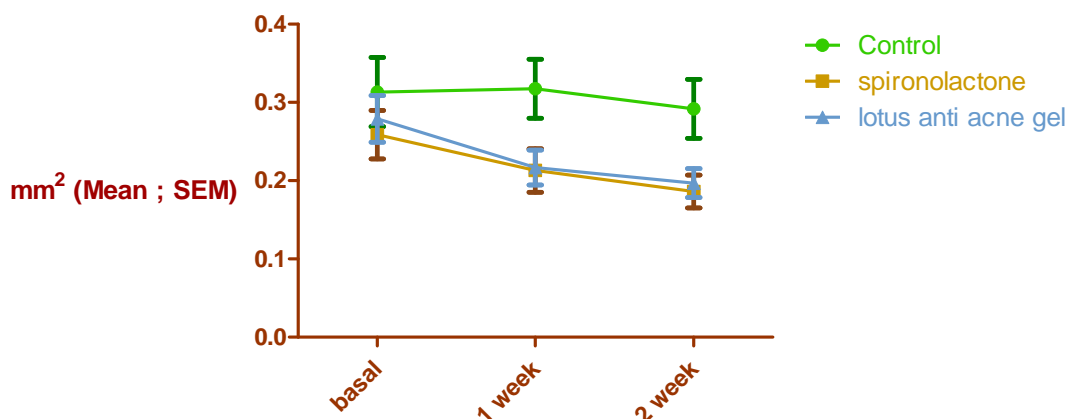
The size of flank organ was calculated. The mean area of left flank organ in control, Spironolactone (1mg/kg), and lotus anti acne gel groups was found to be 0.313, 0.276 and 0.304 respectively.

left flank organ



The mean area of right flank organ in control, Spironolactone (1mg/kg), and lotus anti acne gel groups was found to be 0.310, 0.213 and 0.237 respectively.

Right flank organ



DISCUSSION:

Acne is a major problem among youth. It is a multifactorial disease involving the pilosebaceous unit, and is most frequent and intense in the areas where sebaceous glands are largest and more numerous. There are many drugs and preparations used in the treatment of acne vulgaris such as topical treatment with erythromycin, clindamycin, benzoyl peroxide, azelaic acid and retinoic acid¹. The present study shows the effect of a marketed herbal product in treating acne vulgaris. This result was comparable to topical spironolactone. The herbal anti acne gel showed no side effects and considered safe when compared to other topical therapies which are commonly associated with local or systemic side effects.

The sebaceous glands in the ears of normal, untreated male and female hamsters were observed by stripped skin planimetry. The size of sebaceous glands of normal, untreated male hamsters was found to be approximately 9 times greater than the size of sebaceous glands of normal, untreated female hamsters at the basal region. The densities of sebaceous glands in an area of 1 sqmm were also calculated in both male and female hamsters, and there was no significant difference found in the densities.

Testosterone propionate was injected subcutaneously to enhance sebum production in male and female hamsters at different doses. In female hamsters, the

size of sebaceous glands in the animals with 1mg/kg and 5 mg/kg testosterone propionate was about 4 times and 5 times more than the size of sebaceous glands of normal control animals respectively. The density of sebaceous glands in 1 sq mm area of ear was also calculated. There was no significant difference found in the density of sebaceous glands in the treated animals when compared to normal animals.

In male hamsters, the size of sebaceous glands in the animals with 1mg/kg and 5mg/kg testosterone propionate was about 1.4 times and 1.5 times more than the size of sebaceous glands of normal control animals respectively. The density of sebaceous glands in 1 sq mm area of ear was also calculated. There was no significant difference found in the density of sebaceous glands in the treated animals when compared to normal animals.

The decrease in the sebaceous gland size in ear after application of Spironolactone and herbal anti acne gel was calculated. The area of sebaceous glands of Spironolactone group and herbal anti acne gel group was found to be less when compared to the control group. The percentage reduction in area was calculated by comparing the left ears with the treated right ears of the 3 groups. It was found that there was about 33% and 24% reduction in the size of sebaceous glands of right ear of Spironolactone group and lotus anti acne gel group respectively.

The size of flank organ was calculated. A significant decrease in the treated right flank organs of Spironolactone and herbal anti acne group was observed.

CONCLUSION:

The present study indicates the anti ACNE potential of marketed Herbal gel by decreasing the sebaceous gland size.

REFERENCE:

1. Shwetha K. Topical Herbal Therapies an Alternative and Complementary Choice to Combat Acne. *Research Journal of Medicinal Plant*. 2011;5:650-669.
2. Zouboulis CC, Eady A, Philpott M, et al. What is the pathogenesis of acne? *Exp Dermatol*. 2005;14(2):143-152.
3. Muhammad T. Pathogenesis of acne-Simplified. *Journal of Pakistan Association of Dermatologists*. 2012;20:93-97.
4. Priyanka M, Patidar A, Gupta D, Agrawal S. Treatment of Acne with Herbal Remedie – *Calendula officinalis*: An Overview . *International Journal of Pharmaceutical & Biological Archives*. 2012;2(4):1020-1023.
5. Singh D. Herbal Plants and Propionibacterium Acnes: An Overview. *International Journal of Biomedical Research, North America*. 2011;2(9):486-498.
6. Ebede TL, Arch EL, Berson D. Hormonal treatment of acne in women. *J Clin Aesthet Dermatol*. 2009;2(12):16-22.
7. Winston MH, Shalita AR. Acne vulgaris. Pathogenesis and treatment. *Pediatr Clin North Am*. 1991;38(4):889-903.
8. Kumar S, Chandrashekhara M, Nanjan M, Suresh B. Herbal remedies for Acne. 4[4], 328-334. 2005.
9. Tea Tree Oil. medline plus. <http://www.nlm.nih.gov/medlineplus/druginfo/natural/113.html>.
10. Lutsky BN, Budak M, Koziol P, Monahan M, Neri RO. The effects of a nonsteroid antiandrogen, flutamide, on sebaceous gland activity. *J Invest Dermatol*. 1975;64(6):412-417.
11. Vogel HG. *Drug discovery and evaluation pharmacological assays*. 2nd completely rev., updated, and enl. ed. Berlin: Springer; 2002.
12. Noto G, Pravata G, Bongiorno MR, Bosco M, Arico M. Topical canrenoic acid. Quantification of the antiandrogenic activity in the hamster flank organ. *Int J Dermatol*. 1991;30(11):810-813.
13. Weissmann A, Bowden J, Frank B, Horwitz SN, Frost P. Morphometric studies of the hamster flank organ: an improved model to evaluate pharmacologic effects on sebaceous glands. *J Invest Dermatol*. 1984;82(5):522-525.
14. Plewig G, Luder Schmidt C. Hamster ear model for sebaceous glands. *J Invest Dermatol*. 1977;68(4):171-176.