



CODEN [USA]: IAJPBB

ISSN : 2349-7750

**INDO AMERICAN JOURNAL OF
PHARMACEUTICAL SCIENCES**

SJIF Impact Factor: 7.187

<https://doi.org/10.5281/zenodo.8309675>Available online at: <http://www.iajps.com>

A Case Report

**PIPERACILLIN-TAZOBACTAM INDUCED
THROMBOCYTOPENIA: A CASE REPORT****Khawaja Talha Aziz¹, Malik Hasnat ul Hassan Khan², Javed Miandad³,
Mohammad Saad Waqas⁴, Syed Aftab Ahmed⁵**¹MTI-KTH Peshawar, Pakistan²MTI-LRH Peshawar Pakistan³MTI-LRH Peshawar Pakistan⁴Khyber Girls Medical College, Peshawar Pakistan⁵MTI-KTH Peshawar Pakistan**Abstract:**

Drug-induced thrombocytopenia is a common cause of thrombocytopenia and a long list of drugs are implicated in this phenomenon. There are at least 3 mechanisms implicated in drug-induced thrombocytopenia; bone marrow suppression, immunological and non-immunological thrombocytopenia. We present here a case of a young adult female presenting with a perinephric abscess who was started on broad-spectrum piperacillin-tazobactam. On day 12 of the starting antibiotics there was an abrupt and thereafter rapid decline in her platelet count. After a thorough investigation to rule out other possible causes of thrombocytopenia, drug-induced thrombocytopenia as a possible etiology was suspected. Subsequently, the antibiotic was withheld after a discussion with the hospital hematologist and a blood picture repeated daily thereafter showed a rapid increase in platelet count once the offending agent was withdrawn. The patient thereafter was started on a different class of antibiotic and had a complete recovery and was discharged after a prolonged stay of 33 days.

Corresponding author:**Khawaja Talha Aziz,**
MTI-KTH Peshawar, Pakistan

QR code



Please cite this article in press Khawaja Talha Aziz et al, *Piperacillin-Tazobactam Induced Thrombocytopenia: A Case Report*, Indo Am. J. P. Sci, 2023; 10 (08).

INTRODUCTION:

Thrombocytopenia is defined as a platelet count below $150 \times 10^9/L$, some have suggested a cut-off value of $100 \times 10^9/L$ as appropriate to identify clinically significant thrombocytopenia. (1) Thrombocytopenia can be associated with a variety of conditions, with risks that can range from life-threatening bleeding or thrombosis to no risk at all. At the initial presentation, the cause can be unclear (2). The major pathophysiology of low platelet count includes either decreased platelet production in the bone marrow, peripheral platelet destruction by antibodies, consumption in thrombi, dilution from fluid resuscitation, or sequestration in the spleen. (3)(4)

Drug-induced thrombocytopenia is fairly common and characterized by drug-dependent antibodies that bind to platelets and cause their destruction (5). Several different drugs can cause drug-induced thrombocytopenia (6). It is technically very difficult to identify the antibodies that cause platelet destruction due to a lack of equipment and scarcity of expertise. In most cases, the diagnosis is confirmed by laboratory findings in conjunction with the temporal relation between cessation of the offending drug and rise in platelet count, combined with the elimination of other known causes of thrombocytopenia (7)

Case Presentation:

An 18-year-old girl who had recently undergone an abortion via induction of labor for a 25-week-old intrauterine fetal demise about 10 days back was admitted to the Emergency department of Lady Reading Hospital Peshawar in March 2023 in severe distress complaining of severe left flank and diffuse bilateral lower limb pain along with a high-grade fever. She was hypotensive, tachycardic, tachypneic, and had a toxic appearance. Furthermore, she exhibited left flank and bilateral lower limb tenderness to deep palpation along with a restricted active and

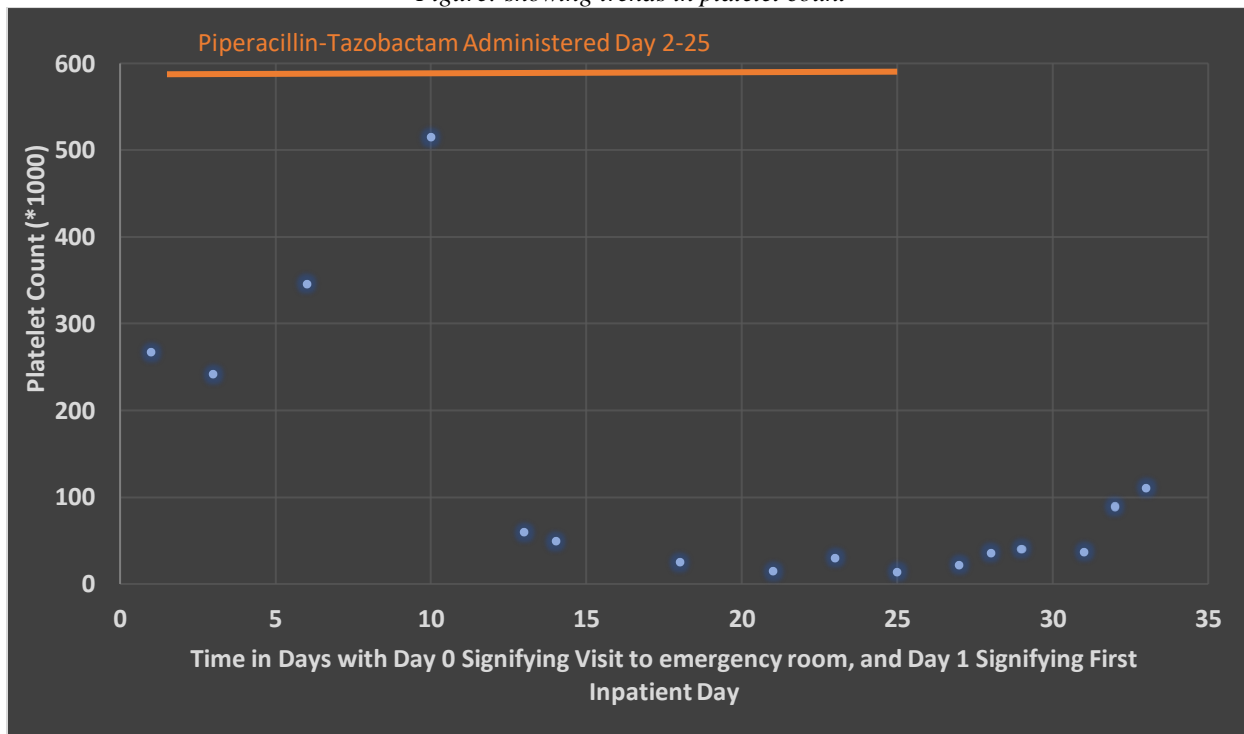
passive range of motion due to pain at the bilateral hip and knee joints. She was managed as a case of septic abortion with immediate stabilization via fluid support along with the administration of IV antibiotics following Blood culture collection. A CT abdomen and pelvis revealed a large 15.5 cm perinephric abscess on the left side that had extended into the iliopsoas. In addition, her blood work revealed a TLC of $12.3 \times 10^9/\mu l$, Hemoglobin of 10.3g/dl, platelet count of $267 \times 10^9/\mu l$, along with a d-dimer of 2695 ng/ml, and a CRP of 22.4 mg/dL. As a result, Image-guided drainage of the abscess was performed with the catheter left in situ. In addition, she was started on Piperacillin-Tazobactam. On the 10th DOA, she had a platelet count of 515, surprisingly in the span of three days i.e by the 13th day of admission it had dropped to 60.2. In addition, she had a persistently elevated WBC count along with normocytic anemia. The WBC count normalized by the 18th date of admission while her anemia resolved by the 25th day of admission.

Repeat CBCs on the following days revealed a rapid decline in the platelet counts reaching a nadir of $14 \times 10^9/\mu l$ on the 21st day of admission. She was transfused 4 packs of Platelets to make up for the deficit leading to a raised platelet count of 30 thousand by the 22nd date of admission. In addition, she was found to have a raised ESR of 116. To rule out infectious etiologies of thrombocytopenia, she underwent serology for dengue, a peripheral smear for malaria, and a blood culture, all of which were found to be negative. Concurrently, she had a normal abdominal examination with no hepatosplenomegaly that was subsequently confirmed with ultrasound. In the meanwhile, her platelet count again dropped to 14 thousand by the 25th date of admission, depicted in the underlying table and figure.

Table: Showing trends in platelet count

Date of Admission	WBC ($\times 10^3$)	PLT ($\times 10^3$)	HGB g/dl	HCT	MCV
1 st	8.4	267	10.3	32.7	83
3 rd	9.4	242	9.9	31	84
6 th	16.6	346	7.34	22	80
10 th	22.8	515	9.3	26.8	81
13 th	16.5	60.2	8.22	24.1	82
14 th	15.5	49.3	10.3	29.9	80
18 th	9	25.2	10.1	30.6	83
21 st	10.5	14.5	9.4	28.9	84
23 rd	8.87	30	9.81	26.5	84
25 th	10.6	14.1	12.3	36.1	80
27 th	5.3	22.2	12.6	36.3	82.
29 th	7.8	35.9	10.7	30.5	82
30 th	12	40.3	10.5	31.3	83
31 st	9.7	37.1	10.3	30.3	83
32 nd	10.5	89	11	33.6	84
33 rd	14	111	12	36.2	85

Figure: showing trends in platelet count



A preliminary diagnosis of drug-induced thrombocytopenia was made and Piperacillin Tazobactam was stopped. Following this, a rising trend in platelet counts was documented on the 26th date of admission. The ESR dropped to 78 while the CRP had dropped to 7.3 by the 28th date of admission. Subsequently, the platelet count reached the normal

range i-e 111 thousand by the 32nd day of admission. Therefore, she was discharged the following day by which time she had regained full active and passive range of motion of the lower limbs and was ambulatory, furthermore, a repeat CT revealed that the abscess collection had shrunk to 4.5 cm while the drain

had collected 600 mL of pus. She finally went home after a prolonged stay of 33 days.

DISCUSSION:

With prolonged use of piperacillin-tazobactam (PTZ), as in our case, 13 days of PTZ therapy there was a rapid decline in platelet count. A high cumulative dose of PTZ has been reported in the literature to be associated with drug-induced thrombocytopenia (8). Drug-induced thrombocytopenia with PTZ is rarely reported in the literature and thus can be overlooked by physicians (9, 10). In hospitalized patient, thrombocytopenia may be attributed to complications such as sepsis. As in our case, after a proper workup for other possible causes of thrombocytopenia was excluded, the possibility of a drug-induced was considered. After a discussion with the hospital hematologist, the antibiotic was stopped for 3 days, and thereafter complete blood counts were repeated. A progressive and rapid increase in platelet count was noted hence confirming our suspicion of PTZ-induced thrombocytopenia.

The exact mechanism of PTZ-induced thrombocytopenia is unclear, some studies have suggested PTZ-induced suppression of bone marrow (11, 12). Others have suggested PTZ-induced platelet activation via membrane antigen and stimulating the body to produce antibodies against the PTZ-platelet complex, which in turn may activate the complement system leading to platelet destruction (13, 14)

REFERENCES:

1. Smock KJ, Perkins SL. (2014). Thrombocytopenia: an update. *International Journal of Laboratory Hematology*, 36(3), 269-278.
2. Arnold DM, Lim W. (2011). A rational approach to the diagnosis and management of thrombocytopenia in the hospitalized patient. *Seminars in Hematology*, 48(4), 251-258.
3. Harker LA, Finch CA. (1969). Thrombokinetics in man. *Journal of Clinical Investigation*, 48(6), 963-974.
4. Bougie DW, Wilker PR, Aster RH. (2006). Patients with quinine-induced immune thrombocytopenia have both "drug-dependent"

- and "drug-specific" antibodies. *Blood*, 108(3), 922-927.
5. Aster RH. (1999). Drug-induced immune thrombocytopenia: an overview of pathogenesis. *Seminars in Hematology*, 36(1 Suppl 1), 2-6.
6. Fekete GL, Fekete L, Ancuceanu R, Ianoși SL, Drăgănescu M, & Brihan I. (2020). Acyclovir induced immune thrombocytopenia: Case report and review of the literature. *Experimental and Therapeutic Medicine*, 20, 3417-3420.
7. Aster RH, Curtis BR, McFarland JG, & Bougie DW. (2009). Drug-induced immune thrombocytopenia: Pathogenesis, diagnosis, and management. *Journal of Thrombosis and Haemostasis*, 7, 911-918.
8. [Piperacillin–tazobactam induced cytopenia in low cumulative treatment doses | BMJ Case Reports](#)
9. Macwilliam JL, Mistry R, Floyd MS Jr, and Baird AD: Piperacillin/tazobactam-induced thrombocytopenia - a delayed response. *BMJ Case Rep.* 2012. [View Article: Google Scholar: PubMed/NCBI](#)
10. Shaik S, Kazi HA, and Ender PT: Rapid-onset piperacillin-tazobactam induced thrombocytopenia. *J Pharm Pract.* 28:204–206. 2015. [View Article: Google Scholar: PubMed/NCBI](#)
11. Ruiz-Irastorza G, Barreiro G, and Aguirre C: Reversible bone marrow depression by high-dose piperacillin/tazobactam. *Br J Haematol.* 95:611–612. 1996. [View Article: Google Scholar: PubMed/NCBI](#)
12. Kumar A, Choudhuri G, and Aggarwal R: Piperacillin induced bone marrow suppression: A case report. *BMC Clin Pharmacol.* 3:22003. [View Article: Google Scholar: PubMed/NCBI](#)
13. Pérez-Vázquez A, Pastor JM, and Riancho JA: Immune thrombocytopenia caused by piperacillin/tazobactam. *Clin Infect Dis.* 27:650–651. 1998. [View Article: Google Scholar: PubMed/NCBI](#)
14. Grégoire C, Brumpt C, Loirat D, Lau N, Bruel C, Philippart F, Couzigou C, Garrouste-Orgeas M, and Missot B: A case of daptomycin-induced immune thrombocytopenia. *Antimicrob Agents Chemother.* 56:6430–6431. 2012. [View Article: Google Scholar: PubMed/NCBI](#)