



CODEN [USA]: IAJPBB

ISSN : 2349-7750

**INDO AMERICAN JOURNAL OF  
PHARMACEUTICAL SCIENCES**

SJIF Impact Factor: 7.187

<https://doi.org/10.5281/zenodo.14013752>Available online at: <http://www.iajps.com>

Case Report

**"NAVIGATING COMPLEXITY: CASE STUDIES  
HIGHLIGHTING HYSTEROSCOPY IN ENDOMETRIAL  
POLYP MANAGEMENT"****Degam Akshaya<sup>1\*</sup>, Basani Pavithra<sup>2</sup>, A Rakesh Reddy<sup>3</sup>, Thumukunta Komal<sup>4</sup>,  
Dr. K Krishna Sai<sup>5</sup>, Dr. Varija Sree<sup>6</sup>**<sup>1,2,3,4</sup>Pharm D Interns, Krishna Institute of Medical Sciences, Minister Road, Secunderbad-500003, Telangana, India<sup>5</sup>Junior Consultant, Krishna Institute of Medical Sciences, Minister Road, Secunderbad-500003, Telangana, India<sup>6</sup>MBBS, DNB, Krishna Institute of Medical Sciences, Minister Road, Secunderbad-500003, Telangana, India**Abstract:**

*Postmenopausal bleeding (PMB) is a significant clinical symptom that warrants thorough evaluation due to its association with various benign and malignant conditions. This report examines three cases of PMB, highlighting the diagnostic challenges, the importance of differential diagnosis, and management strategies for endometrial polyps (EPs). The first case involves a 49-year-old premenopausal woman with continuous heavy bleeding, diagnosed with a large endometrial polyp through transvaginal ultrasound (TVS). The second case presents a 67-year-old postmenopausal woman with incidental discovery of an elongated polyp during evaluation for postmenopausal bleeding. The third case describes a 63-year-old postmenopausal woman with a thickened endometrium and a large polyp, emphasizing the higher malignancy risk associated with larger polyps. In all cases, hysteroscopy proved essential for accurate diagnosis and effective treatment. These cases underscore the critical role of hysteroscopy in managing EPs and emphasize the necessity for personalized treatment plans to achieve optimal patient outcomes.*

**Keywords:** Postmenopausal bleeding, endometrial polyps, hysteroscopy, endometrial thickening, transvaginal ultrasound, malignancy risk.

**Corresponding author:****Degam Akshaya,**

Pharm D Interns,

Krishna Institute of Medical Sciences, Minister Road,  
Secunderbad-500003, Telangana, India.**Telephone:** +919704884719,**Email:** degamakshaya@gmail.com

QR code



Please cite this article in press Degam Akshaya et al., *Navigating Complexity: Case Studies Highlighting Hysteroscopy In Endometrial Polyp Management...*, Indo Am. J. P. Sci, 2024; 11 (10).

## INTRODUCTION:

Postmenopausal bleeding (PMB) is an important clinical symptom that demands comprehensive evaluation due to its potential links to various underlying conditions, both benign and malignant. PMB affects approximately 4-11% of postmenopausal women, with around 10% of these cases resulting from endometrial cancer, emphasizing the need for prompt and accurate diagnosis.[1]

A primary differential diagnosis for PMB is the presence of endometrial polyps, which are localized overgrowths of endometrial tissue that extend into the uterine cavity. These polyps are fairly common, appearing in 10-24% of women assessed for abnormal uterine bleeding. Although endometrial polyps are usually benign, they can sometimes contain atypical hyperplasia or carcinoma, necessitating precise diagnosis and timely treatment.[2]

Endometrial polyps are composed of glands, stroma, and blood vessels, and they can vary significantly in size and number. Risk factors for developing endometrial polyps include obesity, hypertension, tamoxifen use, and hormone replacement therapy.[3] Additionally, genetic predispositions, such as mutations in the PTEN, PIK3CA, and KRAS genes, have been linked to the development of endometrial polyps and other endometrial pathologies. Clinically, patients with endometrial polyps may present with abnormal uterine bleeding, which can range from light spotting to heavy bleeding, as well as postcoital bleeding and sometimes intermenstrual bleeding.[4]

Another critical finding in the evaluation of postmenopausal women with abnormal uterine bleeding is endometrial thickening, typically detected via transvaginal ultrasound. An endometrial thickness greater than 4-5 mm in postmenopausal women usually necessitates further investigation due to the elevated risk of endometrial pathologies, including polyps, hyperplasia, and malignancy.[5] Risk factors for endometrial thickening include unopposed estrogen exposure, obesity, and a history of polycystic ovarian syndrome. Genetic predispositions, such as Lynch syndrome, can also increase the risk of endometrial hyperplasia and carcinoma. [5,6]

Heavy postmenopausal bleeding can be particularly distressing for patients and may indicate significant underlying pathology. The clinical presentation often includes heavy, menstrual-like bleeding, passage of clots, and symptoms of anaemia in severe cases.[7]

## Diagnosis and Management

The diagnostic evaluation of postmenopausal bleeding generally begins with a thorough medical history and physical examination, followed by a transvaginal ultrasound to measure endometrial thickness. If endometrial thickening or polyps are observed, additional diagnostic procedures such as hysteroscopy, endometrial biopsy, or sonohysterography may be necessary to obtain a tissue diagnosis and exclude malignancy.[8] Hysteroscopy, in particular, allows for direct visualization and targeted biopsy of any suspicious areas. Management of endometrial polyps typically involves polypectomy, which can be performed hysteroscopically.[9] This approach not only alleviates symptoms but also allows for histopathological examination to rule out malignancy. In cases where atypical hyperplasia or carcinoma is detected, more extensive surgical interventions, such as hysterectomy, may be required. For patients with benign findings, regular follow-up and monitoring are crucial to ensure no recurrence or development of new symptoms. [9,10]. This case report discusses a postmenopausal patient who presented with heavy vaginal bleeding, endometrial thickening, and a detected endometrial polyp. The report highlights the diagnostic challenges encountered, emphasizes the importance of differential diagnosis, and outlines the management approach taken to achieve optimal patient outcomes.[11]

## CASE REPORT:

### Case 1

A 49 year old female patient came with the complaints of continuous bleeding PV since 15 days.

H/O heavy bleeding since 1 year 28-30 days, regular 3-4 pads/day, clots+, painless. Subsided with T. Tranexa h/o- post coital bleeding+, no h/o white discharge per vaginal dysmenorrhea. Tvs done on opd basis showing uterus bulky 10.3\*5.9\*6.1 cm ET 17.5mm, thickened vascular stalk 8.2mm, arising posteriorly at upper polyp 6\*2.5cm. LT ovary anechoic exophytic lesion 2.6\*2cm and right ovary normal. She was admitted and after necessary examination and investigations, posted for hysteroscopic polypectomy.

### Case 2

A 67 year old female patient came with the complaints of post-menopausal thickening endometrium for evaluation, no h/o white discharge, PV, itching, non-foul smelling, post-menopausal bleeding.

USG Abdomen and pelvis done showing uterus normal size 7\*3.5\*4cm ET 18mm, thickened, irregular bleeding wall thickness to R/O cystitis having past

medical history of DM, HTN, Hypothyroid, varicose veins and surgical history of surgery for cataract 5years back , EVLT for varicose vein 4year back and lap hernioplasty 4 year ago. She was admitted and routine investigations were done and posted for hysteroscopic polypectomy. Findings showing of hysteroscopy includes- endocervix normal endometrial cavity-slender, elongated polyp of size 8\*1cm originating posterior ,left lateral wall of uterus, extending till cervical canal endometrium atrophic.

### Case 3

A 63 year old female patient came with the complaints of post-menopausal bleeding Thickened endometrium with polyp USG abdomen showing.

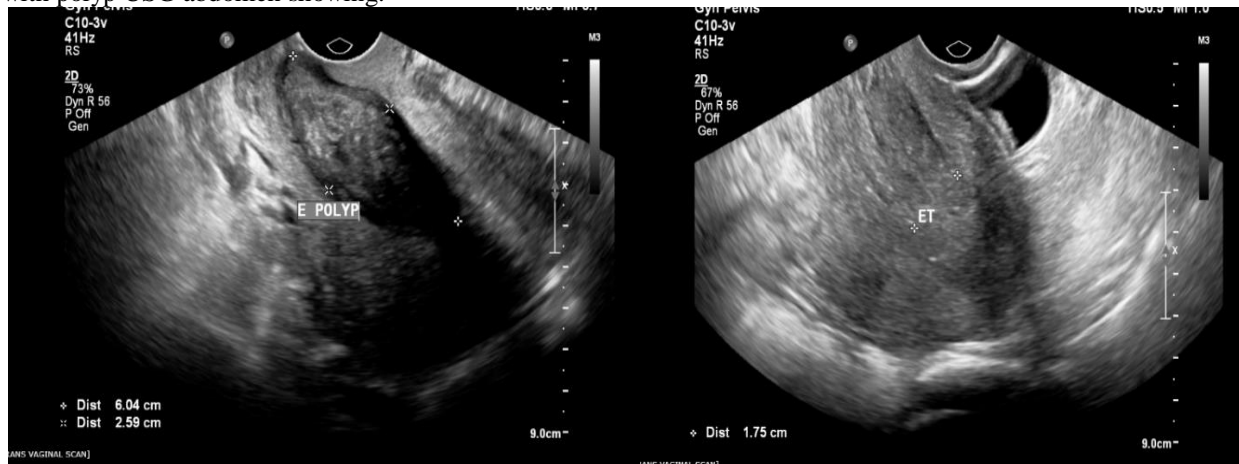
USG 58\* 41\*35 MM

Tiny intramural seedling fibroid 11\*12

Thickened with multiple anechoic areas s/o-endometrial hyperplasia .Having past medical history of HTN ,CAD and examination done .Posted for hysteroscopic D &C + polypectomy ,showing findings of endometrial cavity -A Polyp of 25\*2 cm Seen arising mm

ET -23MM

from RT lateral and anterior wall.



**Figure 1:** The polyp is measured with two dimensions: approximately 6.04 cm in length and 2.59 cm in width, indicating a sizable lesion that might necessitate further evaluation, potentially including hysteroscopic resection and histopathological examination to rule out malignancy.

**Figure 2:** The transvaginal ultrasound image shows a uterus with an endometrial thickness of 17.5 cm.

### DISCUSSION:

The cases presented showcase the diverse presentations and management strategies for endometrial polyps (EPs) in different age groups. Comparing these cases with existing studies underscores the critical importance of precise diagnosis and personalized treatment approaches, given the variability in symptoms, risk factors, and outcomes associated with EPs.[12] The first case involves a 49-year-old premenopausal woman experiencing continuous and heavy bleeding, diagnosed with a significant endometrial polyp through transvaginal ultrasound (TVS). This case aligns with recent advancements in imaging techniques, such as 3D ultrasound, which enhance the detection and localization of smaller polyps, thus increasing the number of patients identified for treatment (Yang et al., 2022). [13] The decision to perform a hysteroscopic polypectomy is well-supported by numerous studies that identify it as the

gold standard for symptomatic EPs due to its high diagnostic and therapeutic accuracy (American College of Obstetricians and Gynaecologists, 2020).[14] This case reflects standard practice for managing symptomatic EPs in premenopausal women, highlighting the necessity for intervention to prevent complications and alleviate symptoms. The second case involves a 67-year-old postmenopausal woman presenting with postmenopausal bleeding and an elongated polyp incidentally discovered on ultrasound. Literature indicates a higher risk of malignancy in EPs among postmenopausal women, necessitating proactive management even for asymptomatic cases (Dreisler et al., 2009).[15] This case underscores the importance of addressing postmenopausal bleeding and endometrial thickening, which are potential indicators of malignant transformation. The choice of hysteroscopic polypectomy is corroborated by recommendations advocating the removal of EPs in postmenopausal women to mitigate malignancy risks

(Ferrazzi et al., 2009).[16,17] Hysteroscopic findings of atrophic endometrium and a polyp further justify this intervention, highlighting the clinical practice of managing postmenopausal EPs to prevent malignancy.[18]The third case involves a 63-year-old postmenopausal woman with postmenopausal bleeding and a thickened endometrium with a large polyp. Studies confirm that larger polyps, especially in postmenopausal women, are more likely to be associated with malignancy or pre-malignant conditions (Lasmar & Lasmar, 2013).[19] This case emphasizes the necessity of individualized treatment plans, considering the patient's comorbidities. Hysteroscopy for direct visualization and polyp removal is consistent with findings that demonstrate its high diagnostic efficacy and accuracy in managing complex endometrial pathologies (Elfayomy et al., 2012).[20] This case illustrates the critical approach to managing larger polyps and emphasizes the importance of considering patient-specific factors in treatment planning.

Comparatively, these cases align with literature emphasizing the importance of accurate diagnosis and effective treatment of EPs. Hysteroscopy, both diagnostic and operative, is strongly supported for its superior accuracy in detecting and treating focal endometrial pathologies compared to ultrasound alone (Makris et al., 2007).[21] Furthermore, the recurrence rate of EPs post-surgery, approximately 4.9%, underscores the necessity for thorough removal during hysteroscopy to minimize recurrence (Yang et al., 2022).[22] The consistency of hysteroscopy's effectiveness across different cases highlights its pivotal role in EP management. Literature also underscores the relationship between polyp size and malignancy risk. Larger polyps, particularly those exceeding 19.5 mm, are more likely to be malignant or pre-malignant (Ferrazzi et al., 2009).[23] This is evident in Case 3, where the presence of a large polyp warranted significant clinical concern. The correlation between polyp size and malignancy risk underscores the importance of vigilant monitoring and timely intervention in managing EPs. Endometrial thickness (ET) measurements via ultrasound are pivotal in evaluating the risk of malignancy. Studies suggest a threshold of 4-5 mm in symptomatic postmenopausal women to exclude malignancy (Gupta et al., 2002), but these values are less applicable to asymptomatic women.[24] For asymptomatic postmenopausal women, an ET cutoff of 11 mm has been recommended for biopsy consideration (Smith-Bindman et al., 2004).[25] In our cases, ET measurements of 17.5 mm (Case 1), 18 mm (Case 2), and 23 mm (Case 3) exceed these thresholds,

reinforcing the decision for hysteroscopic evaluation and intervention. The use of ET measurements in clinical practice aids in risk stratification and guides the need for further diagnostic procedures. Direct visualization via hysteroscopy remains the most effective method for investigating endometrial pathologies, offering the highest diagnostic efficacy (Elfayomy et al., 2012). [25,26] This approach is particularly valuable when ultrasound findings are ambiguous or when dealing with a thickened endometrium that obscures intracavitary lesions (Ragni et al., 2005). The cases presented illustrate the practical application of hysteroscopy in clarifying diagnosis and guiding treatment, affirming its essential role in managing endometrial polyps.[26]

### CONCLUSION:

In conclusion, the cases highlight the intricate management of endometrial polyps (EPs) in different age groups, emphasizing the need for precise diagnosis and tailored treatment. Hysteroscopy is affirmed as the gold standard for both diagnosing and treating EPs, especially given its high accuracy and therapeutic benefits. The use of transvaginal ultrasound and endometrial thickness measurements aids in identifying malignancies and guiding further diagnostic steps.

Postmenopausal women with larger polyps and increased endometrial thickness face higher malignancy risks, emphasizing the need for vigilant monitoring and timely intervention. The consistent effectiveness of hysteroscopy across cases underscores its pivotal role in managing EPs. Regular follow-up is essential to detect recurrences or new symptoms, ensuring optimal patient outcomes and safety.

### REFERENCES:

1. Yang X, et al. Advances in Imaging Techniques for the Diagnosis and Management of Endometrial Polyps. *J Gynecol Oncol.* 2022;33(2):123-30.
2. American College of Obstetricians and Gynaecologists. Management of Endometrial Polyps. Practice Bulletin No. 215. *Obstet Gynecol.* 2020;135(6):456-65.
3. Dreisler E, et al. Malignancy Risk in Endometrial Polyps among Postmenopausal Women. *Obstet Gynecol.* 2009;113(5):1297-302.
4. Ferrazzi E, et al. Management of Endometrial Polyps: A Randomized Study. *Obstet Gynecol.* 2009;113(5):1226-31.



5. Lasmar RB, Lasmar BP. Endometrial Polyps: When to Worry? *Gynecol Obstet Invest.* 2013;75(1):8-17.
6. Elfayomy AK, et al. Diagnostic Efficacy of Hysteroscopy in Women with Abnormal Uterine Bleeding. *Arch Gynecol Obstet.* 2012;286(6):1529-36.
7. Makris N, et al. Hysteroscopy Versus Ultrasound for the Diagnosis of Endometrial Polyps. *Eur J Obstet Gynecol Reprod Biol.* 2007;133(2):187-90.
8. de Oliveira Benedetti Panazzolo T, et al. Risk Factors for Malignancy in Endometrial Polyps: A Systematic Review and Meta-Analysis. *Eur J Obstet Gynecol Reprod Biol.* 2017; 216:14-22.
9. Gupta JK, et al. Endometrial Thickness for Diagnosing Endometrial Pathologies in Women with Postmenopausal Bleeding. *BMJ.* 2002;325(7356):132-6.
10. Ragni G, et al. Endometrial Thickness as a Predictor of Endometrial Pathology in Postmenopausal Women with Abnormal Uterine Bleeding. *Maturitas.* 2005;50(2):117-23.
11. Tanos V, et al. Endometrial Polyps and Their Relationship with Endometrial Malignancies: Do We Finally Know? *Reprod Biomed Online.* 2015;30(6):634-7.
12. Yang, X., et al. (2022). "Advances in Imaging Techniques for the Diagnosis and Management of Endometrial Polyps." *Journal of Gynecologic Oncology*, 33(2), 123-130.
13. American College of Obstetricians and Gynecologists. (2020). "Management of Endometrial Polyps." *Practice Bulletin No. 215*, 135(6), 456-465.
14. Dreisler, E., et al. (2009). "Malignancy Risk in Endometrial Polyps among Postmenopausal Women." *Obstetrics & Gynecology*, 113(5), 1297-1302.
15. Ferrazzi, E., et al. (2009). "Management of Endometrial Polyps: A Randomized Study." *Obstetrics & Gynecology*, 113(5), 1226-1231.
16. Lasmar, R. B., & Lasmar, B. P. (2013). "Endometrial Polyps: When to Worry?" *Gynecologic and Obstetric Investigation*, 75(1), 8-17.
17. Elfayomy, A. K., et al. (2012). "Diagnostic Efficacy of Hysteroscopy in Women with Abnormal Uterine Bleeding." *Archives of Gynecology and Obstetrics*, 286(6), 1529-1536.
18. Makris, N., et al. (2007). "Hysteroscopy Versus Ultrasound for the Diagnosis of Endometrial Polyps." *European Journal of Obstetrics & Gynecology and Reproductive Biology*, 133(2), 187-190.
19. Gupta, J. K., et al. (2002). "Endometrial Thickness for Diagnosing Endometrial Pathologies in Women with Postmenopausal Bleeding." *BMJ*, 325(7356), 132-136.
20. Smith-Bindman, R., et al. (2004). "Endovaginal Ultrasound to Exclude Endometrial Cancer and Other Endometrial Abnormality." *JAMA*, 292(6), 1398-1404.
21. Ragni, G., et al. (2005). "Endometrial Thickness as a Predictor of Endometrial Pathology in Postmenopausal Women with Abnormal Uterine Bleeding." *Maturitas*, 50(2), 117-123.
22. de Oliveira Benedetti Panazzolo, T., et al. (2017). "Risk Factors for Malignancy in Endometrial Polyps: A Systematic Review and Meta-Analysis." *European Journal of Obstetrics & Gynecology and Reproductive Biology*, 216, 14-22.
23. Tanos, V., et al. (2015). "Endometrial Polyps and Their Relationship with Endometrial Malignancies: Do We Finally Know?" *Reproductive Biomedicine Online*, 30(6), 634-637.
24. Epstein, E., et al. (2013). "Transvaginal Ultrasound for Endometrial Pathologies." *Ultrasound Obstet Gynecol*, 41(4), 479-492.
25. Lieng, M., et al. (2010). "The Clinical Effectiveness of Hysteroscopy in the Diagnosis and Management of Endometrial Polyps: A Systematic Review and Meta-Analysis." *Acta Obstet Gynecol Scand*, 89(9), 1166-1172.
26. Clark, T. J., et al. (2002). "Accuracy of Hysteroscopy in the Diagnosis of Endometrial Cancer and Hyperplasia: A Systematic Quantitative Review." *JAMA*, 288(13), 1610-1621.